


Indexed on  
PubMed/MEDLINE

ISSN: 0189-6725



# African Journal of Paediatric Surgery

| Volume 7 | Issue 1 | Jan-Apr 2010 |



Official Journal of Association of Paediatric Surgeons of Nigeria [APSON]  
Endorsed by Pan-African Paediatric Surgical Association [PAPSA]

[www.afrijaedsurg.org](http://www.afrijaedsurg.org)

Published by Medknow Publications

# Occult enterorrhagia from jejunal duplication causing diagnostic dilemma in an infant

Kamalesh Pal, Aladeddin Al-Dajani<sup>1</sup>, Dilip K. Mitra

## ABSTRACT

Occult enterorrhagia in infancy may become obscured and lead to diagnostic dilemma. Abnormal findings on investigative modalities, if not properly interpreted and clinically correlated, might complicate the matter leading to missed diagnosis and chronic anaemia. Occult enterorrhagia is an uncommon presentation of intestinal duplications. We describe the intriguing case of chronic anaemia in an infant, where concomitant endoscopic findings misled the diagnosis of jejunal duplication cyst as the cause of enterorrhagia.

**Key words:** Anemia, duplication cyst, infant, occult enterorrhagia

DOI: 10.4103/0189-6725.59355

## INTRODUCTION

Overt enterorrhagia in infants usually manifests as hematemesis or melena/hematochesia and anaemia.<sup>[1]</sup> The source of bleeding in infants is specific and distinct from children and adults.<sup>[1,2]</sup> However, occult enterorrhagia presents as chronic anaemia and can pose significant diagnostic dilemma. We describe a case report of enterorrhagia in an infant, due to jejunal duplication, presenting as chronic anaemia. We also discuss the diagnostic approach to such a scenario of occult gastrointestinal haemorrhage.

## CASE REPORT

Five-month-old boy from Algeria, presented with pallor to the paediatric hematology clinic. He had no history of rash, jaundice, diarrhoea, bleeding per rectum, regurgitation of food, hematuria, or abnormal bleeding

tendency. Baby had been breast fed with switching to weaning feed at four months of age. There was no lymphadenopathy, hepatosplenomegaly, or fissure/polyp on per rectal examination. Blood work up revealed hypochromic normocytic anaemia, low iron content, and iron binding capacity with normal Hb electrophoresis and G6PD. There was no evidence of bleeding diathesis. Stool microscopy was negative for cyst and ova. Baby was kept on iron supplements and iron rich diets, including liver and vegetables, which he tolerated well. The baby showed improvement in hematocrit, general activity, and iron content. However, evaluation at nine months of age showed further drop in hemoglobin to pretreatment level (8.9 gm %), with no additional symptoms apart from weakness. All the investigations were as before with stool occult blood being positive this time. A diagnosis of occult enterorrhagia was made. Upper and lower GI endoscopy revealed antral gastritis, duodenitis (1st part) and isolated vascular ectasia in the colon (mainly descending colon). Biopsy was positive for *H. pylori* (gastric antrum), but negative for allergic proctocolitis or vascular malformation. Upper GI contrast study and small bowel follow through ruled out any reflux or apparent structural anomaly. Baby was put on triple drug regime for *H. pylori* and iron supplementation was continued. Baby showed some improvement in his hematocrit and general activity. Repeat endoscopy at 11<sup>th</sup> month showed complete resolution of gastric and duodenal lesions. At 15 months of age, he presented with history of melena and hematochesia for two weeks duration and severe pallor. There was no history of fever, diarrhoea, abdominal pain, jaundice, or any rash. On evaluation, he was pale (Hb = 5 gm %), tachycardic, and hypotensive. Local examination ruled out any polyp, fissure, or abdominal mass. He was resuscitated with packed RBCs and was kept on parenteral iron of 6 mg/kg/day. After stabilisation, RBC pool scan showed a faint tracer accumulation at left flank. Subsequent Meckel's scan showed a suspicious area of uptake adjacent to greater curvature of stomach in the left quadrant. A differential of possible bleeding duplication cyst of small gut was made. Exploratory laparotomy revealed a 3 x 2 cm<sup>2</sup> jejunal duplication

Paediatric Surgery Unit of Department of Surgery, <sup>1</sup>Department of Paediatrics, College of Medicine, King Faisal University, King Fahad Hospital of the University, Al Khobar, Kingdom of Saudi Arabia

### Address for correspondence:

Dr. Kamalesh Pal,  
Paediatric Surgery Unit, Department of Surgery, College of Medicine,  
King Faisal University, King Fahad Hospital of the University,  
Al Khobar, 31952, Kingdom of Saudi Arabia.  
E-mail: kamalesh\_pal@yahoo.com

cyst around 50 cms from Duodeno jejunal junction containing fleshy rugous mucosal lining, clots, and communicating with jejunum [Figure 1]. Resection and end-to-end anastomosis of jejunum cured the baby's enterorrhagia without further drop in hemoglobin. Baby at five years follow-up is doing well without any iron supplementation. Histopathology revealed duplication cyst with ectopic gastric tissue and ulceration of adjoining jejunum [Figure 2].

## DISCUSSION

Haemorrhage into the lumen of intestine is defined as enterorrhagia, usually manifested as overt symptoms of hematemesis and/or melena/hematochesia. Sources above ligament of Treitz in infants include esophagitis (commonly due to gastroesophageal reflux disorder), gastritis, hypertrophic pyloric stenosis, and peptic ulcer disease.<sup>[1]</sup> The most common causes of bleeding below ligament of Treitz include: anal fissure, milk protein allergy (allergic proctocolitis), intussusception, Meckel's diverticulum, and intestinal duplication. First two causes being commonly responsible for occult bleeding and last three being responsible for overt bleeding per rectum.<sup>[2]</sup> In endemic areas, parasitic infestation may occasionally cause enterorrhagia in infants.<sup>[3]</sup>

In the clinical scenario of chronic anaemia in this infant (at five month age) with laboratory features of iron deficiency and lack of overt melena/hematochesia, it was natural to make a diagnosis of nutritional anaemia. Clinical and laboratory improvement by iron supplementation in the early phase encouraged to continue the medical therapy. However, persistence of anaemia and lack of complete response to iron supplementation asked for a detailed investigation. Local examination had ruled out anal fissure or

polyp. Stool examination for ova/cyst was negative; however, positive guaiac test led to the diagnosis of occult enterorrhagia. As a protocol for investigating, enterorrhagia and bidirectional endoscopy was done; which revealed, follicular antral gastritis, duodenal mucosal lesions, and isolated vascular ectasias, in the colon, forcing us to entertain the diagnosis of gastro duodenitis. Since biopsy had revealed helicobacter infection, baby was put on antihelicobacter therapy and repeat endoscopy had confirmed resolution of gastric and duodenal lesions. However, chronic blood loss continued to be unresponsive to this therapy as well. Further radiography with small bowel follow through was unremarkable. Enteroclysis was technically not possible in this case in our set up. Recently capsule endoscopy and push enteroscopy are increasingly being used to diagnose source of bleeding from small bowel mucosal and other structural lesions including ulcerated duplications, polyps, vasculitis, and vascular malformations,<sup>[4]</sup> but we did not have access to such facilities. Thus, the initial findings eluded the actual diagnosis till symptoms became overt.

RBC pool scan at the time of massive bleeding showed the suspicious area at left hypochondrium and subsequent Meckel's scan showed a suspicious hot spot adjacent to greater curvature. At this point, our differential got narrowed down to possible duplication cyst and was confirmed later at exploration. RBC pool scan is popular investigation for detecting active haemorrhage; however, it has limited role in occult bleeding. Although, Meckel's scan has a sensitivity up to 80% for detecting ectopic gastric mucosa in Meckel's diverticulum, its sensitivity decreases significantly in the event of massive bleeding with hemoglobin below 11 gm %.<sup>[5,6]</sup> Further, with regard to intestinal duplications, sensitivity of Meckel's scan depends on the size of

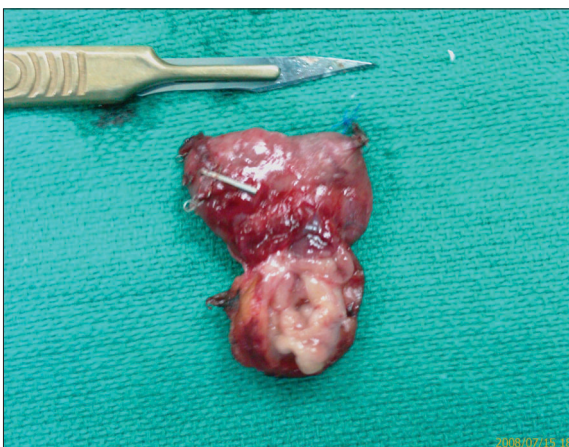

Figure 1: Segment of jejunum with duplication cyst (laid open) showing fleshy rugous mucosa (arrow)

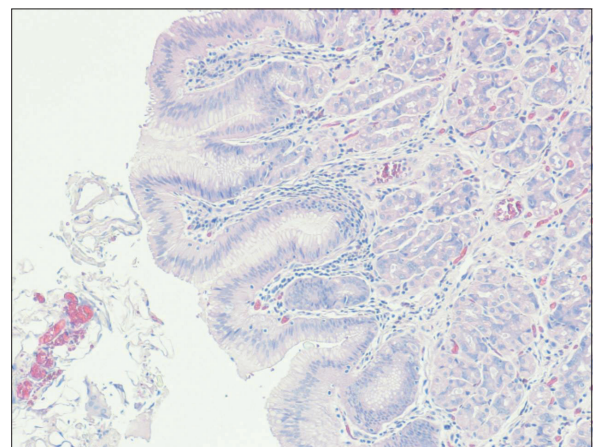


Figure 2: Histopathology showing ectopic gastric tissue (H & E, × 20)

ectopic gastric mucosa, viability of mucosa, overlapping of uptakes by adjoining structures such as, stomach and urinary bladder.<sup>[7–9]</sup> Usually right iliac fossa uptake of radio isotope, synchronously with gastric accumulation, is diagnostic of Meckel's diverticulum. Although, rarely atypical or shifting abdominal scintigraphy has been attributed to Meckel's diverticulum,<sup>[10]</sup> it should commonly lead to suspicion of duplication cysts akin to our case. Although angiography is an option in massive lower GI bleeds, it has technical issues and high rates of complications in children, especially infants. Role of CT/MR angio (MRA) in infancy is also debatable due to lack of enough experience, interpretation difficulties, and motion artifact (especially with MRA), besides other technical issues.<sup>[11]</sup>

Intestinal duplications are congenital cystic or tubular structures at the mesenteric side of intestine, which usually share common wall and contain intestinal lining. Cystic duplications are mostly noncommunicating, and tubular ones are usually communicating to the lumen of bowel. These are known to occur anywhere from oral cavity till rectum; however, majority are seen in the small gut. Approximately 25–39% of these duplications contain ectopic gastric or pancreatic mucosa and can cause ulceration of adjoining normal bowel mucosa leading to enterorrhagia,<sup>[12]</sup> if communicated. Still, noncommunicating duplications can cause enterorrhagia by causing pressure necrosis of adjoining mucosa, intussusception or localised volvulus and gangrene of bowel.<sup>[13]</sup> Although, haemorrhage from intestinal duplications and Meckel's diverticulum are overt,<sup>[14]</sup> these can rarely cause chronic occult enterorrhagia as in our case.

## CONCLUSIONS

Infants presenting with chronic anaemia should be thoroughly investigated for possible enterorrhagia before leveling them as nutritional iron deficiency anaemia, especially if the response to therapy is suboptimal. Jejunal duplication cyst may occasionally present as occult haemorrhage for a long while elusive to standard investigative modalities before

having massive overt haemorrhage and presence of concomitant gastroduodenitis might confound the issue and further delay the diagnosis.

## REFERENCES

1. Arensman RM, Browne M, Madona MB. Gastrointestinal bleeding. In: Grossfeld JL, O'Neill JA, Coran AG, Fronkalsrud EW, editors. *Paediatric Surgery*. 6<sup>th</sup> ed. Philadelphia: Mosby Elsevier; 2006. p. 1386-7.
2. Boyle JT. Gastrointestinal bleeding in infants and children. *Pediatr Rev* 2008;29:39-52.
3. Bestard JJ, Bellasai J, Chamorro LA, Garcete L, Zacur M, Richer Y, *et al.* Uncinariasis in younger infants. *Biol Med Hosp Infant Mex* 1990;47:376-81.
4. Toth E, Lillienau J, Ekelund M, Alumets J, Olsson R, Thorlacius H. Ulcerated small-intestine duplication cyst: an unusual source of GI bleeding revealed by wireless capsule endoscopy. *Gastrointest Endosc* 2006;63:192-4.
5. Swaniker F, Soldes O, Hirschl RB. The utility of technetium 99 m pertechnetate scintigraphy in the evaluation of patients with Meckel's diverticulum. *J Pediatr Surg* 1999;34:760-4.
6. Kong MS, Chen CY, Tzen KY, Hung MJ, Wang KL, Lin JN, *et al.* Technetium-99m pertechnetate scan for ectopic gastric mucosa in children with gastrointestinal bleeding. *J Form Med Ass* 1993;92:717-720.
7. Torgerson CL, Young DW, Vaid YN, Georgeson KE, Kelly DR. Intestinal duplication: Imaging with Tc-99m sodium pertechnetate. *Clin Nucl Med* 1996;21:968.
8. Sfakianakis GN, Conway JJ. Detection of ectopic gastric mucosa in Meckel's diverticulum and in other anomalies by scintigraphy-Indications and methods; a 10years experience. *J Nucl Med* 1981;22:732-8.
9. Reyhan M, Aydin M, Yapar AF, Bal N, Eker D. Scintigraphic Diagnosis of Jejunoileal Duplication. *Clin Nucl Med* 2005;30:66-8.
10. Zwas ST, Czerniak A, Wolfstein I. Unusual scintigraphic presentation of a shifting Meckel's diverticulum. *Clin Nucl Med* 1985;10:252-5.
11. Stunell H, Buckley O, Lyburn ID, McGann G, Farrell M, Torreggiani WC. The role of computerized tomography in the evaluation of gastrointestinal bleeding following negative or failed endoscopy: A review of current status. *J Postgrad Med* 2008;54:126-34.
12. Ilstad ST, Tollerud DJ, Weiss RG, Ryan DP, McGowan MA, Martin LW. Duplications of alimentary tract: clinical characteristics, preferred treatment, and associated malformations. *Ann Surg* 1988;208:184-9.
13. Ein SH. Leading points in childhood intussusception. *J Pediatr Surg* 1976;11:209-11.
14. Wardell S, Vidican DE. Ileal duplication cyst causing massive bleeding in a child. *J Clin Gastroenterol* 1990;12:681-4.

**Source of Support:** Nil, **Conflict of Interest:** None.

### Dispatch and return notification by E-mail

The journal now sends email notification to its members on dispatch of a print issue. The notification is sent to those members who have provided their email address to the association/journal office. The email alerts you about an outdated address and return of issue due to incomplete/incorrect address.

If you wish to receive such email notification, please send your email along with the membership number and full mailing address to the editorial office by email.