



African Journal of Paediatric Surgery

| Volume 11 | Issue 1 | Jan-Mar 2014 | **Special Edition**

In this issue:

- African journal of paediatric surgery: A decade experience of continuous publication
- Reconstruction of bilateral tibial aplasia and split hand-foot syndrome in a father and daughter
- Elastic stable intramedullary nailing of femoral shaft fractures in children
- Laparoscopic treatment of the peritoneo-vaginal duct persistences in children at Sylvanus Olympio Teaching Hospital of Lomé (Togo)
- Comparison of different morphological parameters with duration of obstruction created experimentally in unilateral upper ureters
- Pyeloplasty in children by lumbotomy approach using infant feeding tube as single stent
- Peptic oesophageal stricture in children: Management problems
- Granulomatous appendicitis in children: A single institutional experience



Official Journal of:
Association of Paediatric Surgeons of Nigeria [APSON]
Pan-African Paediatric Surgical Association [PAPSA]

Congenital hernia of the umbilical cord associated with extracelomic colonic atresia and perforation of gut in a newborn

Kamalesh Pal

Quick Response Code:



SUMMARY

Congenital hernia of the umbilical cord (CHUC) is a rare congenital entity compared to more common post-natally occurring umbilical hernia. Although recognized as a distinct entity since 1920s, CHUC is often misdiagnosed as a small omphalocele, resulting in its underreporting. We present the first case report of CHUC associated with extracelomic colonic atresia, complicated by perinatal perforation in a newborn. We also discuss the differentiating features from other anterior abdominal wall defects such as omphalocele and gastroschisis including its embryogenesis.

Key words: Colonic atresia, hernia of umbilical cord, neonate, perforation

INTRODUCTION

Congenital hernia of umbilical cord (CHUC) has been reported sparingly compared with more commonly occurring postnatal umbilical hernia. We report the first case of congenital hernia into the umbilical cord associated with extracelomic colonic atresia and perinatal perforation of gut in a newborn. We also discuss the differentiating features from other anterior abdominal wall defects such as omphalocele and gastroschisis including its embryopathogenesis.

CASE REPORT

This was a case report of a male preterm (35 weeks) baby weighing 1800 g, born to 26-year-old Saudi mother

Division of Pediatric Surgery, Department of Surgery, King Fahad Hospital of the University, College of Medicine, University of Dammam, Al Khobar 31952, Kingdom of Saudi Arabia

Address for correspondence:

Dr. Kamalesh Pal,
Division of Pediatric Surgery, King Fahad Hospital of the University,
University of Dammam, P.O. Box: 40129, Al Khobar 31952,
Kingdom of Saudi Arabia.
E-mail: kamalesh_pal@yahoo.com,

(G3P2) by normal vaginal delivery. There was no history of maternal illness or any congenital anomalies in the family. On examination, the baby was found to have a swelling (5 cm × 4 cm) at the base of umbilical cord [Figure 1] with meconium exuding from a small defect on the swelling. Umbilical cord had normal vessels and attachment to the abdomen with a cuff of skin carried over to the sac. Loops of bowel could be seen through the membrane of the sac. The umbilical ring appeared complete and intact, but somewhat widened. There was no other gross congenital anomaly. Initial impression of congenital hernia into the cord with patent vitello intestinal duct (PVID) was made and was decided for surgical correction. On exploration sac was found to contain loops of distal ileum, ileo-cecal junction, appendix and ascending colon [Figure 2]. There was a perforation on ascending colon with hypoplastic distal bowel. A catheter passed through the perforation got stuck within 2 cm of the ascending colon suggesting a Type I colonic atresia [Figure 3]. Rest of gut was normal. Limited resection and ileo-ascending anastomosis was done after confirming distal bowel patency. Post-operative recovery was uneventful and the child is doing well at 2 years follow-up. Histopathology confirmed the existence of a Type I diaphragm in the ascending colon.

DISCUSSION

Embryologically, during early fetal life, a greater portion of the intestine lie in the proximal part of the umbilical cord, this is called the extracelomic cavity. Normally, the intestines withdraw into the abdominal cavity at about 10-12 weeks gestation, the umbilical ring closes and the extracelomic cavity is thereby obliterated. In rare cases the umbilical ring does not close and in these instances variable portions of the intestines remain in the extracelomic cavity, which persists as congenital hernia into the umbilical cord. Therefore hernia of cord is an entity distinct from other anterior abdominal wall anomalies such as gastroschisis and omphalocele. An

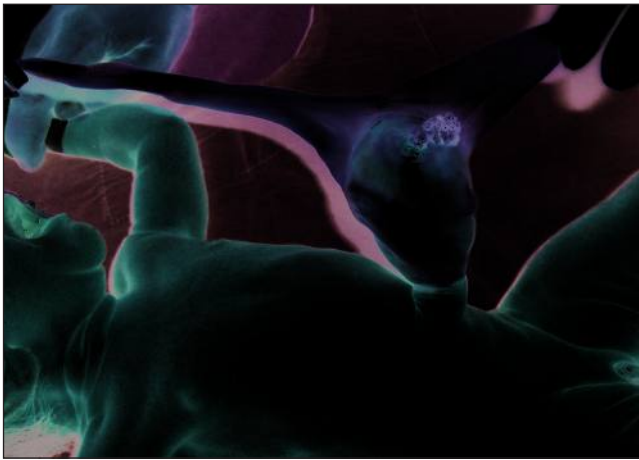


Figure 1: Hernia into the umbilical cord with meconium discharge

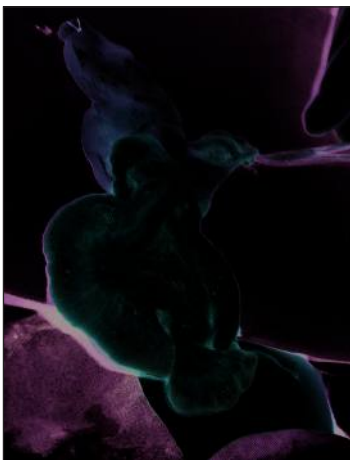


Figure 2: Sac containing dilated distal ileum, ileo-cecal junction, ascending colon with perforation and hypoplastic distal colon

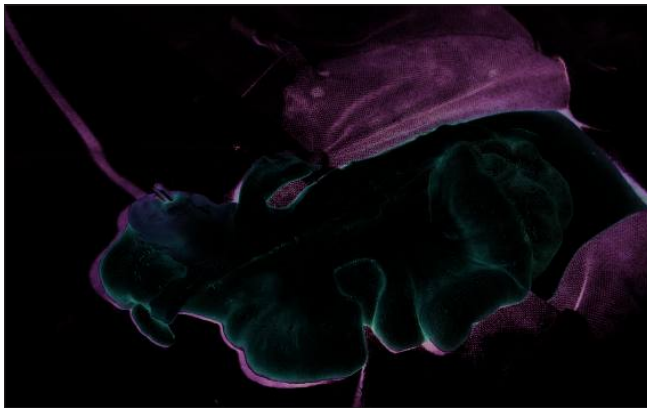


Figure 3: Perforation of the ascending colon with catheter stuck at Type I colonic atresia

intact umbilical ring, absent abdominal wall deficiency, presence of a sac comprising of an outer layer of amnion and inner peritoneum and contents varying from loops of the intestine to any movable intraperitoneal organ (depending on the size of the defect) are the features distinguishing this entity from later two conditions.^[1]

As a rule there is a cuff of skin from one half to one inch wide, which extends from the abdominal wall onto the neck of the sac as seen in our case [Figure 1]. The incidence of CHUC is low (Tow^[2] had reported incidence of 1 in 5000 births) compared to postnatal umbilical hernia, partly because most of these are misdiagnosed as “omphalocele minors.” Few early reports in 1920s to 1930s had shown male preponderance, association with prematurity and familial occurrence.^[2,3] CHUC, usually a benign pathology, may occasionally have meconium discharge from the sac through an associated PVID.^[4] We have reported a case with meconium stained liquor and meconium aspiration syndrome in a newborn with hernia of cord associated with Type III A ileal atresia and perinatal gut perforation.^[5]

In our current case, there was meconium discharge from the sac at birth suggesting perinatal perforation of the gut. We had made an initial impression of PVID until exploration revealed a perforated Type I colonic atresia. We believe this rare association is being reported for the first time.

Frequent clinical instances of intestinal atresias due to intrauterine vascular accidents such as volvulus, intussusception, internal hernia, constriction of the mesentery in a tight gastroschisis or omphalocele defect and even callous umbilical cord clamping have been observed.^[6-9] Therefore, we hypothesize that an early mesenteric vascular accident in the extracelomic herniated bowel could have caused this colonic atresia preventing the loops of the bowel to return to the celomic cavity and thus giving rise to congenital hernia of the cord.

Congenital hernia into the umbilical cord is a distinct anomaly occurring at an early embryological stage compared to omphalocele and gastroschisis and can be detectable by fetal ultrasonography as early as the second trimester.^[10] One should be cognizant of such anomaly especially when there is a swelling at the base of the cord so as to avoid any iatrogenic injury to gut due to close umbilical clamping. Neonatal surgical exploration is indicated to rule out associated intestinal atresia.

REFERENCES

1. Burns CW, Ogryzlo MA. Congenital hernia into the umbilical cord; two cases, one associated with persistent cloaca. *Can Med Assoc J* 1938;39:438-41.
2. Tow R. *Diseases of the Newborn*. New York: Oxford Medical Publication; 1937. p. 224-6.
3. Hempel-Jorgensen P. Familial congenital umbilical hernia. *Ugesk f Laeger* 1929;91:273-4.

4. Jona JZ. Congenital hernia of the cord and associated patent omphalomesenteric duct: A frequent neonatal problem? *Am J Perinatol* 1996;13:223-6.
5. Pal K, Nofal A. Umbilical hernia associated with extracelomic intestinal atresia and perforation of the ileum in a newborn. *Ann Saudi Med* 2007;27:212-3.
6. Nixon HH, Towes R. Etiology and treatment of small intestinal atresia: analysis of a series of 127 jejunoileal atresias and comparison with 62 duodenal atresias. *Surgery* 1971;69:41-5.
7. Okmian LG, Koevamees A. Jejunal atresia with intestinal aplasia. Strangulation of the intestine in the extraembryonic coelom of the belly stalk. *Acta Paediatr* 1964;53:65-9.
8. Landor JH, Armstrong JH, Dickerson OB, Westerfeld RA. Neonatal obstruction of bowel caused by accidental clamping of small omphalocele: Report of two cases. *South Med J* 1963;56:1236-8.
9. Vassy LE, Boles ET Jr. Iatrogenic ileal atresia secondary to clamping of an occult omphalocele. *J Pediatr Surg* 1975;10:797-800.
10. Achiron R, Soriano D, Lipitz S, Mashlach S, Goldman B, Seidman DS. Fetal midgut herniation into the umbilical cord: Improved definition of ventral abdominal anomaly with the use of transvaginal sonography. *Ultrasound Obstet Gynecol* 1995;6:256-60.

Cite this article as: Pal K. Congenital hernia of the umbilical cord associated with extracelomic colonic atresia and perforation of gut in a newborn. *Afr J Paediatr Surg* 2014;11:74-6.

Source of Support: Nil. **Conflict of Interest:** Nil.