



# African Journal of Paediatric Surgery

| Volume 11 | Issue 1 | Jan-Mar 2014 | **Special Edition**

## In this issue:

- African journal of paediatric surgery: A decade experience of continuous publication
- Reconstruction of bilateral tibial aplasia and split hand-foot syndrome in a father and daughter
- Elastic stable intramedullary nailing of femoral shaft fractures in children
- Laparoscopic treatment of the peritoneo-vaginal duct persistences in children at Sylvanus Olympio Teaching Hospital of Lomé (Togo)
- Comparison of different morphological parameters with duration of obstruction created experimentally in unilateral upper ureters
- Pyeloplasty in children by lumbotomy approach using infant feeding tube as single stent
- Peptic oesophageal stricture in children: Management problems
- Granulomatous appendicitis in children: A single institutional experience



Official Journal of:  
Association of Paediatric Surgeons of Nigeria [APSON]  
Pan-African Paediatric Surgical Association [PAPSA]



# Granulomatous appendicitis in children: A single institutional experience

Kamalesh Pal

## ABSTRACT

**Background:** Granulomatous appendicitis (GA) is a rare entity, mostly mentioned in adults. There have been anecdotal case reports describing GA in the paediatric population. This study was aimed at reviewing the cases of appendectomies to assess the incidence and characteristics of GA in children in a tertiary care University hospital. **Materials and Methods:** Records of children (<13 years age) with biopsy proven granulomatous lesions in the appendectomy specimen, treated during 1991-2011, were analysed. Data regarding demography, clinical presentation, radiological findings, intra-operative finding, histology, diagnosis and follow-up were recorded and descriptively analysed. **Results:** Twelve out of 1150 (1.04%) appendectomies were biopsy proven GA. Male to female ratio was 8:4. Four had Yersinia enterocolitis, two had Crohn's disease (CD; one isolated Crohn's Appendicitis, one Ileo-cecal Crohn' with appendicitis) and five were idiopathic. Remaining one case, initially diagnosed as idiopathic GA, developed full blown ileo-cecal CD at 2<sup>nd</sup> month post-operative. Age ranged between 4 and 11 years with inflammatory bowel disease (IBD) affecting older children and Yersinia, seen in younger children. Majority (10/12) remained asymptomatic at a maximum of 5 years of follow-up. Two patients had recurrent symptoms; one with sub-acute obstruction (2 years follow-up) and another with flaring of Crohn's ileitis (2 months follow-up). **Conclusions:** GA in children is a rare entity, with incidence of 1.04% and male preponderance in our series. Idiopathic causes were the most common followed by Yersinia enterocolitis and CD. Although majority remained asymptomatic, IBD should be ruled out in case of recurrence of pain or alteration of bowel habit. Therefore, a long-term follow-up (at least for 5 years) of idiopathic GA is suggested in children.

**Key words:** children, Crohn's, granulomatous appendicitis, idiopathic, Yersinia

## INTRODUCTION

Granulomatous appendicitis (GA) is a rare form of appendicitis described to occur due to varieties of causes such as a foreign body, fungi, parasites, mycobacteria, Yersinia and Crohn's pathology. Often a specific cause is indiscernible and this is designated as "idiopathic GA". Few case series in adult population have reported the incidence of GA between 0.14% and 2% of appendectomies.<sup>[1-3]</sup> There are only anecdotal case reports<sup>[4,5]</sup> with no real cohort study of GA in children hitherto; clearly mentioning the incidence, or specific characteristics. We made an attempt to determine the incidence and characteristics of the cases of GA operated in children at a single tertiary care institution.

## MATERIALS AND METHODS

Institutional Review Board approval was obtained for this retrospective cohort study. Children (<13 year's age) with biopsy proven granulomatous lesions in the appendectomy specimen, treated between January 1991 and December 2011 at King Fahad Hospital of the University, Al Khobar, KSA, were included. Data regarding demography, presentation, radiology, intra-operative finding, histology, diagnosis and follow-up were analysed. Aetiology of GA assigned during the initial treatment and any revision in aetiology thereafter were also noted.

## RESULTS

Out of total of 1150 appendectomies, 12 were biopsy proven GA, i.e., incidence of 1.04%. Male to female ratio was 2:1 (8:4). Four had Yersinia enterocolitis, five were idiopathic, two had Crohn's disease (CD) at surgery

Department of Surgery, Division of Pediatric Surgery, King Fahad Hospital of the University, College of Medicine, University of Dammam, Al Khobar, Kingdom of Saudi Arabia

### Address for correspondence:

Dr. Kamalesh Pal,  
Department of Surgery, Division of Pediatric Surgery, King Fahad Hospital of the University, P. O. Box 40129, Al Khobar 31952, Kingdom of Saudi Arabia. E-mail: kamalesh\_pal@yahoo.com

and the remaining one, initially diagnosed as idiopathic GA, later developed full blown CD. Thus, a total of 3/12 had CD. The age of the children ranged between 4 and 11 years. CD was found in older children (9, 10 and 11 years), whereas *Yersinia* pathology was seen among relatively younger children. Patient demographics, initial diagnosis, histopathological findings, follow-up outcomes are shown in Table 1 and Figure 1. Presentation of right lower abdominal pain was acute in seven children (including one case of acute recurrent attack) and chronic/sub-acute in three children. Two children had interval appendectomies (6<sup>th</sup> and 8<sup>th</sup> weeks following initial attack respectively). Leucocytosis (counts >11,000/cumm was noted in 10/12 cases with neutrophilia (>70%) in eight and lymphophilia (>55%) in two cases. Two cases had normal leukocyte count. In all these cases of GA, ultrasonography was used as the initial imaging modality. Contrast enhanced CT scan was added in four cases with two of them having positive findings; and diagnostic laparoscopy was performed in two other cases with equivocal physical and radiological findings.

Intra-operatively, typical features of suppurative appendicitis was noted in most (8/12) of the cases; in one case there was prominent mesenteric lymphadenopathy (positive for non-caseating and non-suppurative granulomas on histopathology) [Figure 2], one case had frank ileo-colic Crohn's pathology with creeping of fat in mesoappendix [Figure 3], shortened and fibrotic appendices in two cases of interval appendectomies.

*Yersinia* serology was done in 8/12 children which was positive in two cases, stool culture grew *Yersinia enterocolitica* in four children including the seropositive cases.

None of the cases showed fungi, foreign bodies, parasites or acid fast bacilli. Purified Protein Derivative tests done in 7/12 cases post-operatively were negative. Serology for Inflammatory bowel disease (IBD) such as perinuclear anti-neutrophil cytoplasmic antibody (P-ANCA) and anti-saccharomyces cerevisiae antibody (ASCA) were measured in three cases, one case with ileo-colic Crohn's and appendicitis showed ASCA + VE/P-ANCA-VE result.

Follow-up data were available in 10 children for variable period (maximum up to 66 months). There was no follow-up record in two cases (idiopathic GA) possibly due to lack of post-operative symptoms and absence of a policy of scheduled follow-up. Two cases with recurrent abdominal pain and GI symptoms were diagnosed as

CD and sub-acute intestinal obstruction at 2<sup>nd</sup> month and 24 months follow-up respectively.

## DISCUSSION

Appendiceal inflammation with granulomatous histopathology is defined as GA. In adult patients, an incidence of GA in up to 2% of appendectomies has been reported.<sup>[1,2]</sup> Out of several etiological factors those have been implicated, idiopathic and *Yersinia* sp. (*enterocolitica*, pseudotuberculosis) have been the common ones.<sup>[6-14]</sup> This is similar to the frequency of causes in our series. Other causes include fungi, parasites (strongiloides, schistosomiasis), actinomycosis, CD, tuberculosis and foreign bodies.<sup>[6-14]</sup> Granulomas and xanthogranulomas have also been documented in cases of interval/delayed appendectomies, recurrent and chronic appendiceal inflammations.<sup>[15]</sup> However, mostly the actual aetiology is unfounded and is labelled as "idiopathic GA".<sup>[16]</sup>

There is a dearth of literature regarding the incidence and characteristics of GA in paediatric population. In our series, GA was encountered in 1.04% (12 out of 1150 cases) of appendectomies in children <13 years of age. There was a male preponderance with male to female ratio of 2:1 (8 males and 4 females). Age of presentation was variable ranging between 4 and 11 years; with younger children showing *Yersinia* or idiopathic causes while IBD (Crohn's pathology) was encountered among older children.

Predominant feature primary CD of appendix is transmural inflammation characterised by fibrosis and giant cell epithelioid granulomata. Mucosal ulceration, fissuring, cryptitis and abscess formation are characteristics of Crohn's pathology. An accompanying spectrum of acute inflammatory changes is also seen. Idiopathic GAs has somewhat histological resemblance barring the transmural granulomatous inflammation, absence of fissuring mucosal lesions and crypt abscesses [Figure 1].

Isolated or primary Crohn's affecting appendix is rare (reported incidence is <0.2-4.9%)<sup>[6,12,17,18]</sup> although ileo-colonic Crohn's with appendicitis is still far more common (around 24%).<sup>[6]</sup> Nearly 5-10% of the GAs go on to develop full blown Crohn's in the ileum or colon in a period ranging between 3 months and 4 years.<sup>[6,19]</sup> The prognosis of isolated appendiceal Crohn's is much favourable to the full blown disease as the former is met with nearly complete cure and no fistulisation.<sup>[6]</sup> However, the major dilemma remains at distinguishing

**Table 1: Patient data and disease characteristics**

Age/Sex	Presentation	Radiology	Yersinia serology/ Stool culture	Histology	PPD ASCA ANCA	Diagnosis	Follow-up
6 years/M	Acute	USG – thickened appendix, (8 mm), minimal free fluid RIF	Not done	Granulomas, epithelioid cells, no giant cells, caseation or foreign bodies. Acute inflammatory cells present. Fungal stain negative	PPD-VE	Idiopathic GA	One visit post-operative 6 months – asymptomatic
9 years/F	Acute	USG- appendix not visualised	Not done	Epithelioid granulomas with lymphoid cuffing, transmural inflammation with lymphoid aggregates, acute inflammatory infiltrates present	PPD-VE	Idiopathic GA	1 week post-operative-normal. No further visits
10 years/M	Interval Appendectomy 8 weeks post-drainage of appendicular abscess	USG- appendix not visualised	YS-VE SC-VE	Epithelioid granulomas with lymphoid cuffing, transmural inflammation with lymphoid aggregates, submucosal fibrosis and obliteration of lumen seen. No acute inflammatory aggregates	PPD-VE	Idiopathic GA	2 weeks post-operative normal 2 years post-operative-sub acute obstruction-managed conservatively 3 years post-operative normal
8 years/M	Interval Appendicectomy 6 weeks following conservative treatment of appendicular mass	USG- appendiceal thickening, 6 mm, no collection	SC-VE	Transmural epithelioid granulomas, fibrosis and chronic inflammatory infiltrate, fungal and AFB stain negative	PPD-VE	Idiopathic GA	No follow-up
9 years/F	Acute	USG-acute appendicitis with peri-appendiceal collection	SY-VE SC-VE	Trans mural epithelioid granulomas, giant cells, lymphoid aggregates, mucosal ulceration, fissures present, cryptitis and abscess formation present	ASCA+VE P-ANCA-VE	Acute appendicitis with ileo-cecal Crohn's [Figure 3]	Controlled on medical treatment for CD On follow-up 66 months
10 years/M	Acute	USG-appendix not visualised	SY-VE SC-VE	Trans mural epithelioid granulomas, giant cells, lymphoid aggregates, mucosal ulceration, fissures present, cryptitis and abscess formation present	ASCA-VE P-ANCA-VE	Primary appendiceal Crohn's	Post-operative BMFT-normal Asymptomatic at 60 months follow-up
8 years/M	Chronic	USG-appendix not visualised CT-thickened appendix	SC-VE	Transmural inflammation, epithelioid giantcell granulomata, fibrosis, fungal and AFB stain negative	PPD-VE	Idiopathic GA	Asymptomatic at 12 months follow-up
5 years/F	Recurrent sub-acute	USG, CT- inconclusive Laparoscopy- suppurative appendicitis with mesenteric lymphadenopathy	SC+VE	Epithelioid giant cell granulomata, suppurating, acute inflammatory infiltrates with fibrosis and luminal obliteration, fungal and AFB stain negative		Yersinia GA	No follow-up
11 years/M	Acute recurrent	USG and CT- inconclusive Laparoscopy- inflamed appendix wrapped with omentum, ileo-cecum normal	SC-VE	Transmural inflammation, epithelioid giant cell granulomata, fibrosis. Lymphoid aggregates no mucosal ulceration, fissuring or cryptitis	ASCA-VE P-ANCA-VE PPD-VE	Idiopathic GA, laterprogressed to ileo-caecal Crohn's	2 months post-operative Recurrent RIF pain, diarrhoea Diagnosed Crohn's ileitis On BaMFT [Figure 4] Controlled on medical management at 24 months follow-up

*(Continued)*

**Table 1: (Continued)**

Age/Sex	Presentation	Radiology	Yersinia serology/ Stool culture	Histology	PPD ASCA ANCA	Diagnosis	Follow-up
8 years/M	Acute	USG-acute appendicitis	YS+VE SC+VE	Epitheloid giant cell granulomata, suppurating, acute inflammatory infiltrates. Fungal and AFB stain negative mucosal ulcerations present	PPD-VE	Yersinia GA	Asymptomatic until 24 months follow-up
4 years/F	Acute	USG-appendix not visualised CT-acute appendicitis	SC+VE	Epitheloid giant cell granulomata, suppurating, acute inflammatory infiltrates. Mucosal ulcerations present Fungal and AFB stain negative		Yersinia GA	Asymptomatic till 12 months follow-up
6 years/M	Recurrent sub-acute	USG-acute appendicitis, free fluid in RIF	SC+VE	Epitheloid giant cell granulomata, suppurating, acute inflammatory infiltrates. Mucosal ulcerations present, Fungal and AFB stain negative		Yersinia GA	Asymptomatic till 18 months follow-up

PPD: Purified protein derivative; USG: Ultrasonography; RIF: Right iliac fossa; CT: Computed tomography; AFB: Acid fast bacilli; ASCA: Anti-saccharomyces cerevisiae antibody; P-ANCA: Perinuclear anti-neutrophil cytoplasmic antibody; GA: Granulomatous appendicitis; CD: Crohn's disease

the granulomatous inflammation of appendix of Crohn's and idiopathic origin or even predicting their future course. CD in the appendix may form part of a spectrum of subclinical intestinal Crohn's lesions brought to attention at that time by a superimposed episode of acute appendicitis. Thus, it may forewarn a development of widespread disease.<sup>[18,19]</sup>

And thus the follow-up such children following appendectomies is contentious. In our series, two of the GAs eventually developed ileal Crohn's. We believe these two cases presented to our follow-up due to recurrent symptoms. Since, there has been no consensus regarding long-term follow-up of GA in the literature, physicians tend to choose their own protocols, often recurrence of symptoms dictating the hospital visits. It is quite possible to miss out on those cases or misdiagnose who present to a different setup with abdominal complaints particularly suggestive of sub-acute adhesive obstruction, IBD or tuberculosis.

Atypical P-ANCAs and ASCAs are markers for ulcerative colitis (UC) and CD, respectively. Their role as diagnostic serologic markers for IBD appears to be limited, however, mainly due to their lower sensitivity. The combined use of atypical P-ANCA and ASCA test results substantially affects the pre-test-post-test probability in distinguishing UC from CD in patients with IBD. The P-ANCA/ASCA combination is specific for UC, whereas the ASCA/P-ANCA combination is specific for CD. This may be of help in patients in whom

distinction between CD and UC is not obvious with the classic diagnostic tools (patient history, radiologic examination, endoscopy and biopsy).

Serologic Markers in IBD correlated with ileal involvement of CD disease and stricturing as well as with penetrating disease behaviour.<sup>[20]</sup> In all our three cases of CD, there were clinical, radiological and/or intra-operative features diagnostic of CD. ASCA was positive and ANCA was negative in the case with ileo-cecitis and appendicitis. Other two had negative serology. This has made us to devise a policy to follow-up any such case with GA on 2 monthly basis for 1<sup>st</sup> year yearly thereafter for at least 5 years (as majority of post-appendectomy Crohn's have manifested within 6 months to 4 year time line<sup>[18,19]</sup>).

Recently, Yersinia species, both enterocolitica and pseudo-tuberculosis have been increasingly being reported to cause appendicitis, ileo-colitis and mesenteric lymphadenitis.<sup>[7,17]</sup> The histological features of granulomas, lymphoid cuffing, transmural inflammation, mucosal ulceration and cryptitis are indiscernible from the Crohn's pathology. However, suppurative granulomas,<sup>[17]</sup> positive serology or stool culture could incriminate Yersinia as the causative agent, albeit Yersinia could co-exist with Crohn's in rare instances.<sup>[7]</sup> The most definitive diagnostic would be polymerase chain reaction (PCR) test which would further differentiate between the different species of Yersinia. Most of the cases of Yersinia




Figure 1: Idiopathic granulomatous appendicitis showing epithelioid cell granulomas with Langhan giant cells in appendicular mucosa (H and E, ×100)




Figure 2: Idiopathic granulomatous appendicitis showing epithelioid cell granulomas. Note central neutrophilic aggregates in one and Langhan's giant cell in the other (mesenteric lymph node) H and E, ×100




Figure 3: Crohn's disease with acute appendicitis - (a) Terminal ileum showing skip lesions and mesenteric creeping of fat. (b) Appendix showing acute inflammation and fat creeping from mesoappendix

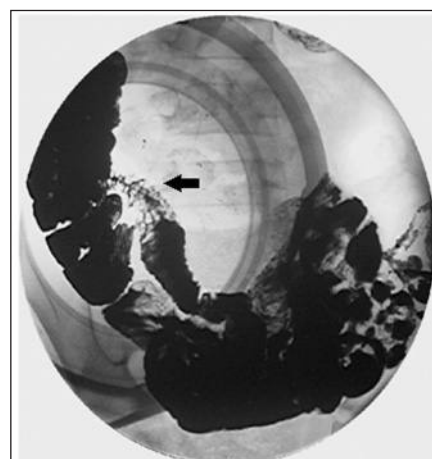


Figure 4: Barium meal follow through of Case 9 at 2<sup>nd</sup> month post-appendectomy showing Crohn's ileitis (arrow)

enterocolitis are self-limiting and usually serology or cultures are not sought after. However, with the increasing incidence of this infection and in the event of suspected appendicitis with chronic diarrhoea/recurrent mesenteric lymphadenitis, it would be prudent to order for Yersinia serology/culture. In case, the histopathology is suggestive of granulomatous pathology with the absence of other aetiologies such as tuberculosis, fungus, actinomycosis etc., a PCR could help identifying the Yersinia GA; especially when serology or stool culture had been omitted. This policy may help to distinguish between true idiopathic, Crohn's and Yersinia GA.

### CONCLUSION

GA in children is a rare entity, with an overall 20 years incidence of 1.04% in this study and has shown a male preponderance. GA in children has varied aetiologies and thus careful interpretation of histopathology and other serological tests is paramount. Idiopathic and Yersinia account for the majority of cases followed

by Crohn's. Idiopathic and isolated Crohn's GAs are difficult to differentiate at presentation in childhood. Thus idiopathic GA should have long-term follow-up to monitor for development of IBD.

### REFERENCES

1. Mizushima T, Ito T, Mizuno H, Udatsu Y, Miyazaki Y, Imakita M, et al. Idiopathic granulomatous appendicitis treated surgically with long-term follow-up: Report of a case. *Surg Today* 2007;37:690-3.
2. AbdullGaffar B. Granulomatous diseases and granulomas of the appendix. *Int J Surg Pathol* 2010;18:14-20.
3. Tucker ON, Healy V, Jeffers M, Keane FB. Granulomatous appendicitis. *Surgeon* 2003;1:286-9.
4. Yayla D, Alpman BN, Dolek Y. Granulomatous appendicitis in a 12-year-old boy. *J Pediatr Surg* 2010;45:e27-9.
5. Listernick R. A 12-year-old girl with abdominal pain and fever. *Pediatr Ann* 2006;35:784, 787-9.
6. Allen DC, Biggart JD. Granulomatous disease in the vermiform appendix. *J Clin Pathol* 1983;36:632-8.
7. Lamps LW, Madhusudhan KT, Greenson JK, Pierce RH, Massoll NA, Chiles MC, et al. The role of Yersinia enterocolitica and Yersinia

- pseudotuberculosis in granulomatous appendicitis: A histologic and molecular study. *Am J Surg Pathol* 2001;25:508-15.
8. Adebamowo CA, Akang EE, Ladipo JK, Ajao OG. Schistosomiasis of the appendix. *Br J Surg* 1991;78:1219-21.
  9. Meshikhes AW, Chandrashekar CJ, Al-Daolah Q, Al-Saif O, Al-Joaib AS, Al-Habib SS, et al. Schistosomal appendicitis in the Eastern Province of Saudi Arabia: A clinicopathological study. *Ann Saudi Med* 1999;19:12-4.
  10. Badmos KB, Komolafe AO, Rotimi O. Schistosomiasis presenting as acute appendicitis. *East Afr Med J* 2006;83:528-32.
  11. Kojima M, Morita Y, Shimizu K, Yoshida T, Yamada I, Togo T, et al. Immunohistological findings of suppurative granulomas of *Yersinia enterocolitica* appendicitis: A report of two cases. *Pathol Res Pract* 2007;203:115-9.
  12. Felekouras E, Kontos M, Kyriakou V, Hatzianagnostou D, Dimarogona K, Papalampros E, et al. *Strongyloides stercoralis* infection as a cause of acute granulomatous appendicitis in an HIV-positive patient in Athens, Greece. *Scand J Infect Dis* 2002;34:856-7.
  13. Luncă S, Romedea N. Actinomycosis of the appendix. Case report. *Rev Med Chir Soc Med Nat Iasi* 2004;108:640-3.
  14. Guo G, Greenson JK. Histopathology of interval (delayed) appendectomy specimens: Strong association with granulomatous and xanthogranulomatous appendicitis. *Am J Surg Pathol* 2003;27:1147-51.
  15. Ariel I, Vinograd I, Hershlag A, Olsha O, Argov S, Klausner JM, et al. Crohn's disease isolated to the appendix: Truths and fallacies. *Hum Pathol* 1986;17:1116-21.
  16. Timmcke AE. Granulomatous appendicitis: Is it Crohn's disease? Report of a case and review of the literature. *Am J Gastroenterol* 1986;81:283-7.
  17. Yang SS, Gibson P, McCaughey RS, Arcari FA, Bernstein J. Primary Crohn's disease of the appendix: Report of 14 cases and review of the literature. *Ann Surg* 1979;189:334-9.
  18. Bronner MP. Granulomatous appendicitis and the appendix in idiopathic inflammatory bowel disease. *Semin Diagn Pathol* 2004;21:98-107.
  19. Ho P, Law WL, Choy C, Chan GS, Chu KW. Granulomatous appendicitis progressing to Crohn's disease with bleeding complication. *ANZ J Surg* 2003;73:554-6.
  20. Bossuyt X. Serologic markers in inflammatory bowel disease. *Clin Chem* 2006;52:171-81.

**Cite this article as:** Pal K. Granulomatous appendicitis in children: A single institutional experience. *Afr J Paediatr Surg* 2014;11:26-31.

**Source of Support:** Nil. **Conflict of Interest:** Nil.