

REVIEW ARTICLE

A Treatise on Intestinal Duplications

Kamalesh Pal

Department of Surgery, Division of Pediatric Surgery, College of Medicine, University of Dammam, King Fahd Hospital of the University, Al Khobar, Kingdom of Saudi Arabia

Correspondence: Dr. Kamalesh Pal, Department of Surgery, Division of Pediatric Surgery, College of Medicine, University of Dammam, King Fahd Hospital of the University, P.O. Box 40129, Al Khobar 31952, Kingdom of Saudi Arabia. E-mail: kpal@uod.edu.sa

ABSTRACT

Duplications of the alimentary tract are unusual congenital anomalies that often present a diagnostic, as well as therapeutic challenge to the treating surgeon. These lesions occur infrequently and are often not suspected until encountered intraoperatively. Due to the complicated anatomy and involvement of the adjacent bowel, appropriate management requires familiarity with the anatomy and clinico-pathological characteristics. This review article is a treatise on intestinal duplications which addresses the current understanding, their epidemiology, classification, etiogenesis, management options and prognosis.

Key words: Classification, intestinal duplications, surgery

ملخص البحث:

تعتبر ازدواجية الجهاز الهضمي عيبًا خلقيًا ولاديا غير معتاد وتشكل تحديًا تشخيصيًا وعلاجيًا للجراح المعالج. وتحدث هذه الازدواجية بصورة نادرة وفي الغالب لا يتم تشخيصها إلا عند اكتشافها أثناء الجراحة. وبالنظر إلى التعقيد التشريحي والباثولوجي للأمعاء المجاورة فإن معالجة هذه الحالة تحتاج إلى معرفة بالخصائص التشريحية والباثولوجية لهذه المشكلة. تعنى هذه المقالة بتصنيف وابتدئولوجية وخيارات المعالجة لازدواجية الجهاز الهضمي وتطورها.

INTRODUCTION

Synonyms and history

The term intestinal duplication has been assigned several names including enterocystomas, enterogenous cysts, supernumerary accessory organs, ileum duplex, giant diverticula and unusual Meckel's diverticulum.^[1] Reginald Fitz first used the term intestinal duplication in 1884,^[2] but it was not widely used until popularized by Ladd in 1937^[3] and classified by Gross in the 1950s.^[4] Ladd recommended that the term "alimentary tract duplications" be applied to those congenital malformations that arise on the mesenteric side of the involved alimentary tract and share a common blood supply with the bowel. His observations consolidated the

classification of this entity and clarified its differentiation from other cystic malformations of the alimentary tract.

Definition

Intestinal duplications consist of a group of congenital anomalies characterized by a well-developed coat of smooth muscle, an epithelial lining representing mucus membrane of the normal gastrointestinal tract and frequently intimately attached to/communicating with some portion of the gastrointestinal tract.^[2]

INCIDENCE

Current literature consists of a spread of case reports or small case series. No center has a long series to ascertain actual incidence. Although the exact incidence is unknown, in 1961 Potter reported two cases in more than 9000 fetal and neonatal autopsies.^[5] The small intestine is most frequently involved, whereas gastric, duodenal, rectal and thoracoabdominal involvement are relatively rare. In one series of 28 children, thoracoabdominal duplication cysts were encountered in 20% of the cases.^[6] Synchronous gastrointestinal duplications occur in up to 15% of patients.^[7]

Access this article online

Quick Response Code:



Website:

www.sjmms.net

DOI:

10.4103/1658-631X.149651

Etiology

The etiology of alimentary tract duplications has not been well-established. Hypotheses have included persistence of embryonic diverticula during the development of the alimentary tract, intrauterine vascular accidents, recanalization and fusion of the embryologic longitudinal folds.^[8] Abortive twinning has also been proposed as one possible causative factor of the extensive complete duplications of the colon and genitourinary system that occasionally occur. A hypothesis to explain such an occurrence has been proposed as the initial developmental abnormality in the gastrulation stage which results in a split notochord in the fetus. During early embryogenesis, the notochord is open so that the endoderm of the yolk sac and the ectoderm of the notochord are fused, and the neuro-enteric canal connects the yolk sac with the amnion. As part of the development of the split notochord, it has been proposed that an endo-ectodermal adhesion between the cord and the yolk sac results in the persistence of an endomesenchymal tract between the yolk sac and the amnion. Thus, the endomesenchymal tract has been held responsible for the anomalies of the entire gastrointestinal system. However, not all duplications are compatible with this theory.

CLINICAL PRESENTATION

Although most of duplications are diagnosed incidentally, the symptomatic presentation depends upon the size, communication with the gut and the location:

- Cervical, lingual and hypopharyngeal duplications present with respiratory distress that may be life-threatening and may thus require rapid diagnosis and treatment.
- Thoracic and thoracoabdominal duplications may cause respiratory distress by airway or lung compression in younger children; however, in older patients, heartburn or melena has been reported, which is probably caused by the presence of gastric mucosa in one-third of the patients with thoracic and thoracoabdominal duplications. Hemoptysis, a very unusual presentation due to the duplication cyst communicating with bronchus or within lung parenchyma has also been reported.^[9]
- Gastric duplications usually present (in children younger than 1 year) with vomiting, poor feeding, failure to gain weight and a palpable mass on physical examination. Hypertrophic pyloric stenosis is a common misdiagnosis in such infants. The mucosal lining of the cysts often resembles gastric epithelium

and may result in melena or hematemesis due to acid peptic disease. There have been instances where the initial presenting symptom in an adult has been an infiltrating adenocarcinoma arising in a duplication cyst of the stomach.^[10]

- Duodenal duplications contain ectopic gastric mucosa in up to 15% cases,^[11] which predisposes the patient to peptic ulcer syndrome-like features leading to painless gastrointestinal hemorrhage and/or perforation. Duplications that extend into the liver^[11] are generally diagnosed after the onset of high intestinal obstruction or hemorrhage that may be accompanied by icterus or pancreatitis. Transdiaphragmatic extension of such lesions are known, which mandates an investigation of both the chest and abdomen in case one is found in a patient in either location. Duodenal duplications are also known to present as acute pancreatitis, pseudopancreatic cysts, obstructive jaundice and rarely with elevated CEA levels.
- Small intestine duplications: Clinical presentation depends on the type, size, location and mucosal lining of the duplication and whether it communicates with the intestine. Small cystic duplications can be a lead point for intussusceptions^[12] or can result in volvulus, whereas long tubular duplications with proximal communication drain poorly and retention of intestinal contents leading to massive distention. This can lead to obstruct the adjacent intestine by compression and or volvulus. Distal communication is more common and more difficult to diagnose because of the paucity of symptoms, than the proximally communicating variety. Gastric mucosa in duplication can lead to ulceration and perforation. The diagnosis is often not established before surgery.

Colonic duplications

- Cystic colonic duplications are either asymptomatic or present as abdominal masses that may be accompanied by pain. Bleeding may be observed despite lower prevalence of ectopic gastric mucosa in colonic duplications. Newborns may present with volvulus or acute intestinal obstruction resulting from a weighted mass forming an axis.
- Tubular colonic duplications are usually asymptomatic, but may present with duplicated genitalia or sometimes a second anal orifice behind the normal one.
- Rectal duplications: Presenting features of colonic or presacral duplications may include constipation, rectal bleeding, hematochezia, rectal prolapse,

hemorrhoids, fistula-in-ano and perirectal abscess besides presenting as a mass behind the anus. Such duplications have presented in adults with malignant transformations.

- In summary, intermittent vomiting especially before the age of one is seen in about 50%, abdominal pain in 50%, abdominal distension in 30%, palpable mass in 20%, peritoneal signs in 13%, blood mixed stools in 6%, fever in 6% and constipation in 6%.^[13]

ANATOMY OF DUPLICATIONS

Distribution

Approximately 75% of duplications have been reported as located within the abdominal cavity, while the remaining are intrathoracic (20%) or thoraco-abdominal (5%). Jejunal and ileal lesions are the most commonly encountered abdominal lesions (53%), followed by mediastinal (18%), colonic (13%), gastric (7%), duodenal (6%), rectal (4%), thoracoabdominal (2%) and cervical (1%).^[14]

Classification

Based on physical appearance

Seventy-five percent of duplications are cystic with no communication with the adjacent intestine, while the remaining duplications are tubular structures that may or may not have one or more direct communications through the common septum. Usually, such communications are located at the distal end.

Pathological classification

- Parenteral cystic type (in the mesentery, cystic, most common),
- Parenteral canal type (in the mesentery, tubular, second most common)
- Parietal cyst type (intramural, third commonest)
- Enteral septum type (intraluminal due to septae, rare)
- Solitary type (seems pedunculated, not intimately attached to the gut, rare).^[15]

Vascular classification

- Type 1 (Parallel type): Duplication is on the mesenteric border of the intestine and has independent blood supply through the vasa recta, which is separated from the straight artery of the bowel. It is not covered by mesentery. Therefore, such duplications can be resected easily without compromising the adjoining bowel.
- Type 2: In the Intramesenteric type, the duplication is in-between the leaves of the mesentery and the

straight arteries arch over the duplication to reach the bowel. It is sometimes technically demanding to resect these duplications without compromising/sacrificing the adjoining bowel as the vasculature is sometimes common to both or is difficult to separate the vessels from the cyst.^[16]

Gross pathology

All intestinal duplications contain at least one layer of smooth muscle and some type of intestinal mucosal layer lining the lumen. These cysts are often attached intimately to the adjacent segment of normal GI tract from which it may be difficult to separate, especially if there has been an infective episode. As mentioned previously, the mucosal lining within the duplicated gut does not necessarily correspond with the adjacent normal intestine. It may display components of several different types of GI tract mucosa or at times respiratory or squamous epithelium,^[17] especially in lingual or at times cervical duplication cysts. Non-communicating duplications typically contain clear alkaline fluid, except in those cases where gastric mucosa is present (25%) which secretes acidic fluid. In addition, non-activated pancreatic enzymes may also be observed in those cases where ectopic pancreatic tissue within the duplication lesion is present.^[18]

The histochemical pattern was studied in a group of alimentary tract duplications ($n = 12$) using special stains such as PAS, AB-PAS, and high iron diamins-AB stains.^[19] The majority (11/12) had gastric mucosa in varying stages of maturation. Two cysts had an additional small gut and bronchial wall mucosa. One intramucosal rectal cyst was lined exclusively with primitive rectal mucosa. The cyst showed a variable pattern of mucin histochemistry ranging from neutral mucin to sulfo and sialomucins. A correlation has been made between the type of mucins and the age of patients. Older infants (7 months or older) had neutral mucins or focal positivity for sulphomucins, whereas younger infants (1 month or younger) had a mixture of sulfo-, sialo- and neutral mucins.

Cervical duplications

These are generally duplications of the esophagus, contain clear mucoid fluid and may be associated with vertebral anomalies.

Thoracic and thoracoabdominal duplications

As many as one third of these lesions have a second or third duplication cyst below the diaphragm,^[1] which may be in continuity or detached from the primary lesion; therefore,

the diagnostic imaging should always include the abdomen. Almost all patients with thoracic/thoracoabdominal duplications have vertebral anomalies that in some instances may also involve the spinal cord [Figures 1 and 2].

Gastric duplications

Gastric duplications are generally cystic and are located on the greater curvature. These do not communicate with the stomach lumen.

Duodenal duplications

These duplications do not generally communicate with the intestinal lumen. Duodenal duplications can arise from the bile ducts or the pancreas.

Small intestinal duplications

Most small intestinal duplications are located adjacent to the distal small bowel. These may be cystic or tubular [Figures 3 and 4], and are situated on the mesenteric border, often sharing a common muscular wall and blood supply with the native intestine. Multiple small intestinal duplications may be present.

Colonic duplications

Colonic duplication cysts may be isolated or have an external fistula to the skin, urinary tract, or normal colon. A tubular duplication of the colon is often associated with duplication of the anus, or external genitalia.

Classification by Kottra and Dodds^[20] of colonic duplications provides practical guidance for the management.

Type I

Duplications limited to the alimentary tract and situated above the peritoneal reflection. These could be cystic

(type Ia), tubular (type Ib) or double barrel type (Ic) with one or multiple communication/s with the gut.

Type II

These are tubular colonic duplications associated with duplication of genitourinary tracts.

Type IIa

Tubular duplications with double genitalia, double urethra and bladder. There are separate perianal ani on either side of midline. There is no communication with genitourinary system.

Type IIb

There is an internal fistula between the duplication and the genitourinary system.

Type IIc

Tubular duplications with imperforate anus. There is no internal fistula between genitourinary tract and the duplication. However, the lower urinary tract may be duplicated.

Rectal duplications

Rectal duplications occur in the retrorectal space. They may present as chronic constipation or occasionally with recurrent perianal sepsis.^[21]

The following associated anomalies are common with duplications:

Approximately 15-50% of alimentary duplications have associated anomalies.^[22,25] Vertebral anomalies are seen in mediastinal (15%) and thoracoabdominal (50%) duplications. Up to 100% of neuroenteric cysts have a vertebral defect with varying degrees of intraspinal extension. Tubular hind gut duplications, especially those extending below the line of peritoneal reflection are associated with genitourinary malformations.

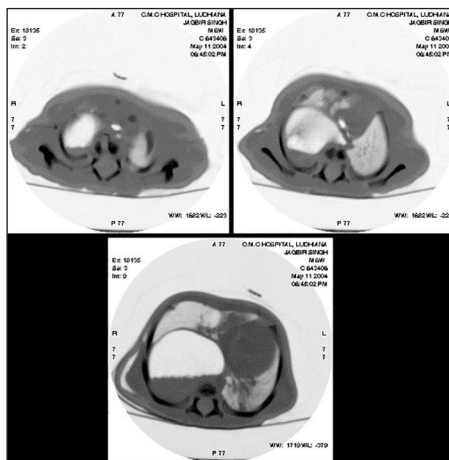


Figure 1: Thoracic duplication of esophagus with anterior spinal defect in a 6-month-old male presenting with respiratory distress. Thoracotomy, excision of cyst and repair of anterior meningocele was done.

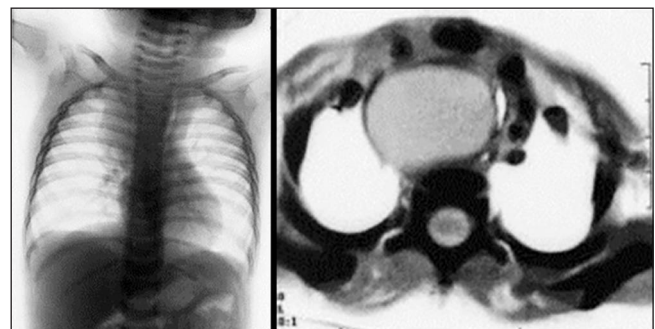


Figure 2: Plain X-ray showing upper mediastinal widening and vertebral defects. CT scan thorax shows enhancing rim of an esophageal duplication cyst. This was excised by right thoracotomy.

Preoperative evaluation

Imaging studies

- Plain radiographs of the chest in different views may reveal a space-occupying lesion in the mediastinum, deviation or distortion of the air column in the trachea, esophageal shadows and vertebral defects. Thoracic duplications are often incidentally discovered on chest radiographs performed for some other complaints. They have a characteristic enhancing ring that can be revealed by contrast enhanced computerized tomography or magnetic resonance imaging (MRI).
- Contrast studies are helpful in demonstrating the mass effect and displacement of normal alignment of adjacent structures.
- In cases of gastrointestinal bleeding, heterotopic gastric tissue can be detected by radio-isotope labeled technetium scans.
- Ultrasonography is increasingly being used successfully in the diagnosis of abdominal duplications. Ultrasound examinations have the added benefit of revealing associated genito-urinary or other intra-abdominal anomalies. Recently, endoscopic ultrasonography has been utilized to accurately delineate pathology especially when dissection of the esophagus is suspected.
- Computed tomography (CT) scan: CT scan, especially multi detector CT of the chest or abdomen is useful in establishing a diagnosis of alimentary tract duplication during the preoperative workup and may be used to evaluate synchronous distant lesions once a single duplication has been identified.
- Magnetic resonance imaging: MRI is now preferred over CT scan as radiation is avoided in young patients. It may be necessary if there are neurologic symptoms of spinal cord compression/involvement or a vertebral anomaly is seen, which may be indicative of intra-spinal cysts. This is sometimes difficult to perform in young patients, as they need to be heavily sedated to stop them from moving.
- Magnetic resonance cholangiopancreatography (MRCP) is useful in differentiating duodenal duplications from choledochal cysts, and also in planning further management.
- Genitogram and/or cystourethrogram in hind gut duplications with associated anomalies may be indicated.

- Prenatal ultrasonography has occasionally detected these enteric cysts, especially of large size, which has been treated successfully by aspiration to facilitate delivery.

Endoscopy

- ERCP for duodenal duplications: Although a valuable tool, may not be of much use for pediatric patients as this facility may not always be available. This has now mostly been replaced by noninvasive MRCP.
- Bronchoscopy may be performed to evaluate the trachea in cervical esophageal duplications, especially those presenting with hemoptysis.
- Genitoscopy and cystoscopy are indicated in hind gut duplications with associated genitourinary malformations.

SUSPECTED CASE OF DUPLICATION

Children with space-occupying lesions in the chest and associated vertebral defect [Figure 2] with obscure GI bleed or with recurrent sub-acute intestinal obstruction (recurrent volvulus) are suspected of having intestinal duplications. CT scan and Technitium pertechnetate scan are the most indicated preoperative investigations.^[24,25]

Laparoscopy has of late become a useful diagnostic and therapeutic tool in situations of mediastinal duplication with transdiaphragmatic extension to rule-out or excise any intra-abdominal cyst, or to evaluate an obscure GI bleeding (Duplication cyst/Meckel's diverticulum if found to be the cause, can be treated by laparoscopy).^[26]

Surgical treatment

Surgical excision or mucosectomy is the treatment of choice for all types of duplications, especially in view of increased reports in literature about malignant degeneration of these malformations.^[10,27-30] In principle irrespective of location, total excision is the preferred method of treatment for alimentary tract duplications. If it is considered unsafe due to anatomical considerations, the decision can be either mucosectomy or internal drainage (to be avoided) provided the gastric tissue if present has been removed.

Most duplications share a common blood supply with the normal bowel and therefore, it may be necessary to perform segmental resection of the adjacent bowel. Otherwise, one may excise or "shell out" the cyst if there is an adequate plane of separation between the cyst and the mesentery with its blood supply. Mucosal stripping, after opening the cyst has also been described for such a cyst, which is an attempt to excise may endanger vital structures [Figure 5]. If excision is not possible, for example because




Figure 3: Cystic ileal duplication causing intestinal obstruction.

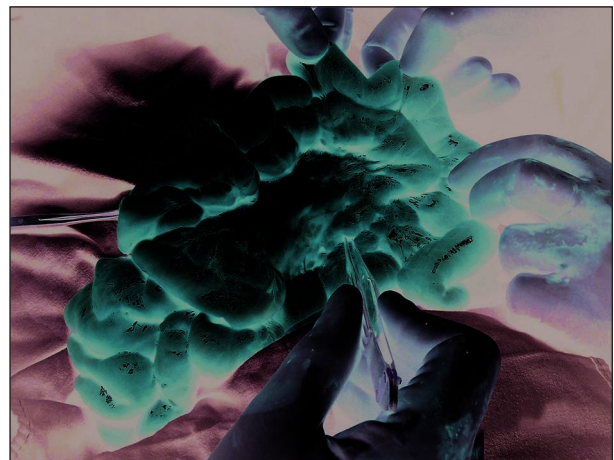


Figure 4: Long tubular duplication of small intestine presenting as melena in a 2 months old infant.

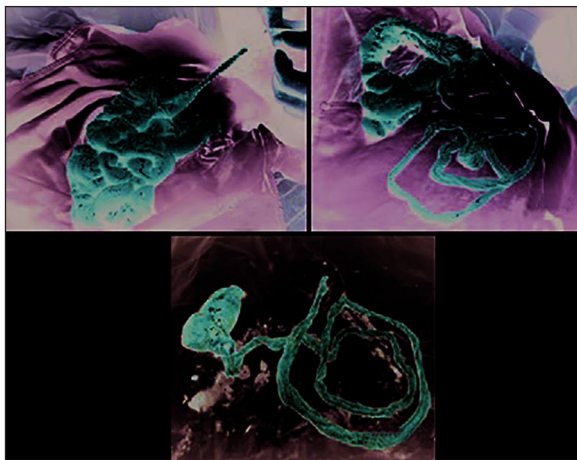


Figure 5: Mucosal stripping of tubular duplication and resection of cystic end having intestinal communication. Histopathology showed presence of ectopic gastric tissue causing hemorrhage.

of proximity to the biliary or pancreatic ducts, an internal drainage procedure commonly employing a Roux-en-Y loop may be performed. However, if this is planned, it must be determined preoperatively whether gastric mucosa is present (with technetium scan). If it is, it must be excised to prevent future ulceration. In colonic and rectal duplications below the peritoneal reflection, endoscopy of the urogenital tract is performed to rule-out associated anomalies:

- Cervical esophageal duplications: Surgical treatment involves the excision of the cyst., If it is not possible to excise the cyst, total mucosectomy is also advised.
- Thoracic and thoracoabdominal duplications: Such duplications occupy the posterior mediastinum. A posterolateral thoracotomy (preferably muscle sparing) and excision of the cyst is desirable. It is a simple procedure and postoperative recovery is uneventful. Care should be taken to avoid injury to the esophagus while shelling out the duplication. In case of difficulty, a segment of common musculature may be left behind.

In those cases where the anatomy is obscure, the cyst is opened and the mucosa stripped, sometimes with difficulty and loss of blood. Combined thoracoabdominal cysts make up for fewer than 2% of all duplications. If staged excision is planned, or only the cyst in one area is to be excised, the duplication that remains after the primary excision should be removed early to avoid its distension resulting from reactionary accumulation of secretions/hemorrhage which at times can be very rapid and life-threatening especially if within the chest.

- Gastric duplications: In most cases, resection can be accomplished without entering the stomach by peeling it off or resecting the shared wall between the stomach and the duplication. Gastric resection is generally not required. A limited excision of the common wall of the stomach may be indicated in cases of difficult dissection. If the lumen is entered accidentally, it can be carefully closed with nonabsorbable sutures.
- Duodenal duplications: Although, as mentioned earlier, surgical resection is the treatment of choice, drainage of the duplication cysts into the duodenum or into a Roux limb of the jejunum is an acceptable alternative if there is any risk of injury to the biliary or pancreatic ductal system. Preoperative endoscopic retrograde cholangiopancreatography (ERCP), percutaneous transhepatic cholangiography (PTC), or magnetic resonance cholangiography (MRCP), or if necessary intraoperative cholangiography (more commonly employed) can help delineate exact anatomy if it is necessary to evaluate the involvement of the biliary/pancreatic ducts. These studies may also distinguish between duodenal duplication and a choledochal cyst if the diagnosis is unclear. Excision should be undertaken if gastric mucosa is present to

avoid later ulceration. Marsupialization and external drainage, erstwhile methods are simply mentioned for information only, but rejected.

- Small intestine duplications: Segmental resection along with the adjacent intestine is the preferred treatment for small cystic or short tubular duplications. Unresectable cystic duplications (in the absence of gastric mucosa) may be drained into a Roux limb. Long tubular duplications that cannot be resected or cannot be separated because of their length can be managed by mucosal stripping through multiple incisions (Wrenn's technique),^[31] or by diversion into the stomach.

Colonic duplications

Cystic duplications

In cases of smaller cysts, a complete excision of the duplication and its attached normal colon is preferred. However, because long colonic duplications generally have communication with the normal colon, creating another internal communication by excising a small part of the common wall to permit re-entry from the duplication into the normal colon to prevent accumulation of debris is sufficient.

Tubular duplications

If the duplication has a common wall with a normal rectum and has a peritoneal opening, the duplication can be connected transanally by excising part of the common rectal wall through the anus using a stapler. Smaller duplications may also be treated by excising the intervening fistula wall (common wall between cyst and rectum), making it part of the common rectum. When tubular duplications extend below the peritoneal reflection, and are associated with abnormalities of the genitourinary tract, preoperative cystoscopy and vaginoscopy/hysteroscopy should be performed to identify the duplication, fistula, or other abnormalities of the bladder, urethra or genital tract.

Rectal duplications

The general approach involves the transanal exposure of the cyst by incising the posterior rectal mucosa to drain the cyst and stripping the mucosal lining. Total excision may also be performed via the transanal, posterior sagittal or transcoccygeal (Kraske) approach.

MINIMAL ACCESS SURGERY

As with many types of surgical interventions, several reports^[26,32] have been published promoting the use of laparoscopy/thoracoscopy for a definitive diagnosis and treatment of alimentary tract duplications. These modalities are particularly helpful in managing

transdiaphragmatic, transabdominal or enteric duplications.^[33]

CONSERVATIVE TREATMENT

The preferred treatment of gastrointestinal duplications is excision. However, in colonic duplications, which feature communication proximally and distally between the duplication and the normal colon, the administration of stool softeners and enemas can improve symptoms.

In complex colonic duplications with duplication of genitourinary system, a conservative approach should be taken to maintain unobstructed lumens of colon, genitourinary tract and the duplication.

COMPLICATIONS AND LONG-TERM OUTCOME

Complications related to the discovery of an intestinal duplication cyst include bowel obstruction and hemorrhage. Because most intestinal duplications are cystic and appear adjacent to the ileum requiring a limited resection, complications related to surgical intervention are typically non-specific and include postoperative bleeding, infection, and bowel obstruction. However, in patients with large tubular duplications, injury to the normal intestine with resultant short bowel syndrome must be considered. Other complications include a few reports of intestinal carcinomas found within duplication cysts. Long term outcome in a majority of duplications is favorable. Complex colonic duplications and tubular duplications where a long segment of small bowel had to be excised carry poor outcome as these children are likely to develop short bowel syndrome.

REFERENCES

1. Ildstad ST, Tollerud DJ, Weiss RG, Ryan DP, McGowan MA, Martin LW. Duplications of the alimentary tract. Clinical characteristics, preferred treatment, and associated malformations. *Ann Surg* 1988;208:184-9.
2. Fitz RH. Persistent omphalomesenteric remains: Their importance in the causation of intestinal duplication, cyst formation and obstruction. *Am J Med Sci* 1884;88:50-57.
3. Ladd WE. Duplications of the alimentary tract. *South Med J* 1937;30:363.
4. Gross RE. Duplications of the alimentary tract. In: *The Surgery of Infancy and Childhood*. Philadelphia:Saunders; 1953. p. 221-45.
5. Potter EL. *Pathology of the Fetus and Newborn*. 2nd ed. Chicago: Year Book Medical, Arnold Edward; 1961. p. 101-3.
6. Bhat NA, Agarwala S, Mitra DK, Bhatnagar V. Duplications of the alimentary tract in children. *Trop Gastroenterol* 2001;22:33-5.
7. Stern LE, Warner BW. Gastrointestinal duplications. *Semin Pediatr Surg* 2000;9:135-40.
8. Knight J, Garvin PJ, Lewis E Jr. Gastric duplication presenting as a double esophagus. *J Pediatr Surg* 1983;18:300-1.

Pal: Intestinal duplication

9. Singal AK, Bhatnagar V, Mitra DK. Oesophageal duplication cyst causing neonatal haemoptysis. *Trop Gastroenterol* 2004;25:99-100.
10. Kuraoka K, Nakayama H, Kagawa T, Ichikawa T, Yasui W. Adenocarcinoma arising from a gastric duplication cyst with invasion to the stomach: A case report with literature review. *J Clin Pathol* 2004;57:428-31.
11. Macpherson RI. Gastrointestinal tract duplications: Clinical, pathologic, etiologic, and radiologic considerations. *Radiographics* 1993;13:1063-80.
12. Boleken ME, Kaya M, Ozardali I, Kanmaz T, Yücesan S. Neonatal cecal cystic duplication mimicking intussusception. *Pediatr Int* 2006;48:172-3.
13. Kuo HC, Lee HC, Shin CH, Sheu JC, Chang PY, Wang NL. Clinical spectrum of alimentary tract duplication in children. *Acta Paediatr Taiwan* 2004;45:85-8.
14. Pintér AB, Schubert W, Szemlédy F, Göbel P, Schäfer J, Kustos G. Alimentary tract duplications in infants and children. *Eur J Pediatr Surg* 1992;2:8-12.
15. Han F, Ji S, Sun Y, Li Z, Tao W. Pathological classification and diagnosis of intestinal duplication. *Chin Med J (Engl)* 1997;110:332-4.
16. Li L, Zhang JZ, Wang YX. Vascular classification for small intestinal duplications: Experience with 80 cases. *J Pediatr Surg* 1998;33:1243-5.
17. Burkart CM, Brinkman JA, Willging JP, Elluru RG. Lingual cyst lined by squamous epithelium. *Int J Pediatr Otorhinolaryngol* 2005;69:1649-53.
18. Lavine JE, Harrison M, Heyman MB. Gastrointestinal duplications causing relapsing pancreatitis in children. *Gastroenterology* 1989;97:1556-8.
19. Mathur M, Gupta SD, Bajpai M, Rohatagi M. Histochemical pattern in alimentary tract duplications of children. *Am J Gastroenterol* 1991;86:1419-23.
20. Kottra JJ, Dodds WJ. Duplication of the large bowel. *Am J Roentgenol Radium Ther Nucl Med* 1971;113:310-5.
21. Flint R, Strang J, Bissett I, Clark M, Neill M, Parry B. Rectal duplication cyst presenting as perianal sepsis: Report of two cases and review of the literature. *Dis Colon Rectum* 2004;47:2208-10.
22. Fallon M, Gordon AR, Lendrum AC. Mediastinal cysts of foregut origin associated with vertebral abnormalities. *Br J Surg* 1954;41:520-33.
23. Superina RA, Ein SH, Humphreys RP. Cystic duplications of the esophagus and neurenteric cysts. *J Pediatr Surg* 1984;19:527-30.
24. Lecouffe P, Spycykerelle C, Venel H, Meuriot S, Marchandise X. Use of pertechnetate ^{99m}Tc for abdominal scanning in localising an ileal duplication cyst: Case report and review of the literature. *Eur J Nucl Med* 1992;19:65-7.
25. Waterston T, Lyall MH, Longrigg N, Wisbey ML. Diagnosis of intestinal duplication by ^{99m}Tc-pertechnetate scanning. *Br J Surg* 1980;67:419-20.
26. Lee KH, Yeung CK, Tam YH, Ng WT, Yip KF. Laparoscopy for definitive diagnosis and treatment of gastrointestinal bleeding of obscure origin in children. *J Pediatr Surg* 2000;35:1291-3.
27. Horne G, Ming-Lum C, Kirkpatrick AW, Parker RL. High-grade neuroendocrine carcinoma arising in a gastric duplication cyst: A case report with literature review. *Int J Surg Pathol* 2007;15:187-91.
28. Hata H, Hiraoka N, Ojima H, Shimada K, Kosuge T, Shimoda T. Carcinoid tumor arising in a duplication cyst of the duodenum. *Pathol Int* 2006;56:272-8.
29. Kuraoka K, Nakayama H, Kagawa T, Ichikawa T, Yasui W. Adenocarcinoma arising from a gastric duplication cyst with invasion to the stomach: A case report with literature review. *J Clin Pathol* 2004;57:428-31.
30. Radich GA, Altinok D, Adsay NV, Soulen RL. Papillary adenocarcinoma in a small-bowel duplication in a pregnant woman. *AJR Am J Roentgenol* 2006;186:895-7.
31. Wrenn EL. Tubular duplication of the entire small intestine. *Surgery* 1962;52:484.
32. Schleaf J, Schalamon J. The role of laparoscopy in the diagnosis and treatment of intestinal duplication in childhood. A report of two cases. *Surg Endosc* 2000;14:865.
33. Martínez-Ferro M, Laje P, Piaggio L. Combined thoraco-laparoscopy for trans-diaphragmatic thoraco-abdominal enteric duplications. *J Pediatr Surg* 2005;40:e37-40.

How to cite this article: Pal K. A treatise on intestinal duplications. *Saudi J Med Med Sci* 2015;3:8-15.

Source of Support: Nil, **Conflict of Interest:** None declared.