

Rare Pediatric Hernias

DK Gupta, Shilpa Sharma, Kamlesh Pal

All pediatric surgeons are well versed with the repair of congenital inguinal hernias. However, there are times when they are confronted with rare hernias. Rare forms of the inguinal hernia are encountered more frequently when approached by the laparoscopic technique than during the open approach.¹ Routine video recording during laparoscopy provided an objective and absolute picture of the true incidence of these unusual forms of the hernia. On retrospective evaluation of these videos, direct hernias were found in 2.2%, femoral hernias in 1.1%, hernias en pantaloon in 0.7% and a combination of indirect, direct, and femoral hernia in 0.4% cases.¹

FEMORAL HERNIA

Femoral hernia is very rare in children and its diagnosis remains a challenging problem in childhood.² The incidence is 0.5-1% of all cases of pediatric groin hernias.²⁻⁴ Femoral hernias are seen more frequently in girls.

In case of the femoral hernia, the defect is through an anatomic triangle surrounded by the inguinal ligament above, the lower border of the pubic bone medially and the femoral vein laterally. The hernia follows the space below the inguinal ligament through the femoral canal. The canal lies medial to the femoral vein and lateral to the lacunar ligament. A femoral hernia is more prone to incarceration or strangulation as it protrudes through a narrow neck.

The swelling during its last part of reduction may be seen to reduce through a defect inferior to the inguinal ligament. The diagnosis is confirmed during operation.

Femoral hernias occur at any age, but are extremely rare in infancy.⁵ The hernia is more common on the right side. The duration of symptoms may range from a few days to many years. A correct diagnosis can only be made preoperatively in only 12-70% of the cases, in different series.^{2,4-7} Childhood femoral hernia is often missed clinically because of difficulty in eliciting their clinical signs.⁸

The most common mode of presentation is a recurrent painless lump in the upper part of the groin on the medial side of the thigh. The swelling reduces with manual compression. If the swelling persists even after the repair of the inguinal hernia, the diagnosis should be revised and the possibility of femoral hernia should be kept in mind. The femoral hernias may be diagnosed during surgery at a negative exploration for a clinically diagnosed inguinal hernia. During an operation for inguinal hernia, it is essential to think of the presence of the femoral hernia when a non-obiterated processus vaginalis is not found.^{4,8} Rarely, the child may present with an incarceration. The rate of irreducible femoral hernia may be quite high (48%).⁷

The differential diagnosis is either an inguinal hernia or a recurrent inguinal hernia. An irreducible femoral hernia needs to be differentiated from the inguinal lymph nodes.

The sensitivity of high resolution ultrasonographic (USG) study in the diagnosis of inguino-crural hernias has been reported to be higher (87.5%) than that of the clinical examination (72%).⁹ Similarly, the sensitivity in the diagnosis of complications in these hernias was reported to be significantly high on high resolution USG (85%) as compared to clinical examination (36%).⁹ A femoral hernia should

positively be excluded if the operative findings at inguinal exploration are inconsistent with the preoperative signs and in any child with a suspected recurrent inguinal hernia.

Repair

Femoral hernia has been treated using a variety of techniques such as classic tissue-based and prosthetic mesh repairs. In children, an excision of the sac and repair of the femoral canal is curative.³ The operation can be done from above or below the inguinal ligament. The author's approach is to repair the femoral hernia with a transverse incision placed below the inguinal ligament. As the sac carries with it a good amount of femoral fat, the sac needs to be separated well and identified from the fatty tissue before closed securely.

In McVay's tissue-based repair, the Cooper's ligament is approximated with the conjoined tendon, through an inguinal incision placed just above the medial side of the inguinal ligament. This type of hernia repair results in an unwanted tension.¹⁰ The Cooper's ligament is though strong yet it lacks the elasticity. Therefore, sutures may cut through the tissues in the postoperative period. McVay's Cooper ligament repair with the advantage of covering all potential hernia sites in the myopectineal orifice has been used to repair the femoral hernias in children. Authors have not experienced any recurrence after surgical repair of the femoral hernia with the approach below the inguinal ligament.

The well-known advantages of tension-free hernia repair led to the development of new techniques for femoral hernia repair using prosthetic material. In 1974, Lichtenstein and colleagues have described 'plug' technique for femoral hernia repair with a recurrence rate less than 2%.¹¹

Recently, femoral defect has been repaired successfully in children using a mesh plug. There were no complications after a follow-up period for 2 years.¹² In a series of 712 inguinal hernias in 542 children, repaired laparoscopically, direct hernias were found in 2.3%, femoral hernias in 1%, hernias en pantalon in 0.7%, and a combination of indirect and femoral hernia in 0.2%.¹³

Laparoscopic groin exploration and femoral hernia repair has some distinct advantages. The procedure is

safe and effective even in the pediatric patients.¹⁴ The advantages of the laparoscopic approach include its technical ease, feasibility as an outpatient procedure, cord structures remaining untouched, the superior diagnostic ability, simultaneous repair of the bilateral hernias and clear visualization of the anatomy.¹³

The incidence of postoperative recurrence varies from 0-13% in different series.^{5,6} A correct preoperative diagnosis will lead to appropriate surgical approach and management, thus avoiding the unnecessary morbidity and preventing unnecessary re-operations.⁶

RICHTER'S HERNIA

A Richter's hernia is defined as a herniation of the antimesenteric border of the bowel through a fascial defect.

As only a portion of the circumference of the bowel is involved, the bowel may not be obstructed, even if the hernia is incarcerated or strangulated, and the patient may not present with obstructive symptoms. Richter's hernia can occur with any of the various abdominal hernias and is particularly dangerous, as a portion of strangulated bowel may be reduced unknowingly into the abdominal cavity, leading to perforation and peritonitis. The patient may complain of pain or have tachycardia and fever due to the strangulation.

LITTRE'S HERNIA

This term is given to herniation of the Meckel's diverticulum through an inguinal hernia. It is extremely rare to happen. A Littre's hernia is defined as any hernial sac which contains a Meckel's Diverticulum.¹⁵ It has been reported in association with inguinal, umbilical, femoral, sciatic, ventral, and lumbar hernias.¹⁵ This hernia is rare, particularly in children, in whom the umbilical hernia is reported to be the most common variety. Littre's hernia is difficult to diagnose, but should be suspected in patients with gastrointestinal bleeding, incompletely reducible hernias, and hernias with fecal fistulae.¹⁵ It may be confused with cryptorchidism when Meckel's diverticulum adheres to and envelops the testicle making palpation of the gonad difficult.

The recommended treatment is resection of the Meckel's diverticulum from within the opened hernial sac followed by herniorrhaphy.¹⁵

VENTRAL HERNIA

This is commonly seen in children as follow-up of conservatively managed abdominal wall defects. The hernia size may be small or large, with a narrow or wide neck (Fig. 47.1). The contents are small bowel loops but liver may also be projecting out in the sac if the size of the hernia is more than 5 cm in diameter. The contents are usually not reducible completely as there are dense adhesions between the under surface of the skin and liver or the intestine. The rectus muscles are wide apart, thinned out and weak, forming the neck of the hernia. All ventral hernias should be repaired, preferably before 1 year of age so that the contents can be reduced and the rectus muscles can be approximated in the midline. With this, the abdominal cavity also gets a chance to grow with the age of the patient. Various options available to repair the ventral hernia include:

Primary Repair of the Defect

after reducing the hernial contents inside the abdominal cavity (Fig. 47.1). In case of difficulty in bringing the muscles together in the midline, additional techniques may be adapted and these include; stretching or the mobilization of the abdominal wall from lateral sides, raising of the anterior rectus sheath vertical flaps on one or both sides and suturing these together in front of the intestine. In cases of anticipated difficulty in closing the hernia, a slow pneumoperitoneum may be

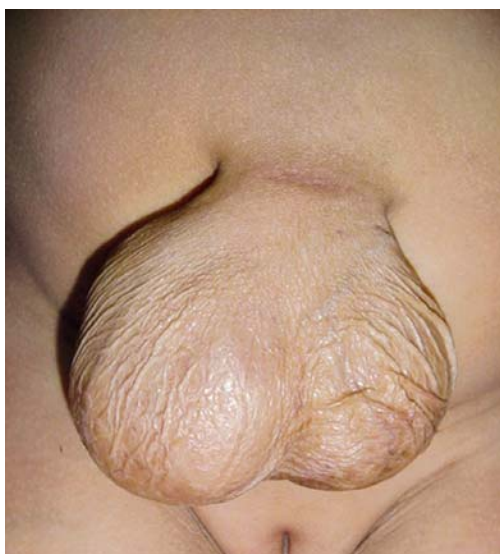

Fig. 47.1: A small ventral hernia in a girl that can be repaired primarily

introduced to increase the size of the abdominal cavity well in advance.

Moderate Sized Defects

Prolene mesh prosthesis may be used to fill the gap between the rectus muscles if these can not be approximated. The available skin is used to cover the mesh. If the same is not sufficient to cover the defect, alternate materials like dura, pericardium, cultured skin are used till the complete healing of the wound takes place. The mesh is removed after many months or years when the abdominal cavity has grown in size and the rectus muscles can be brought together in the midline.

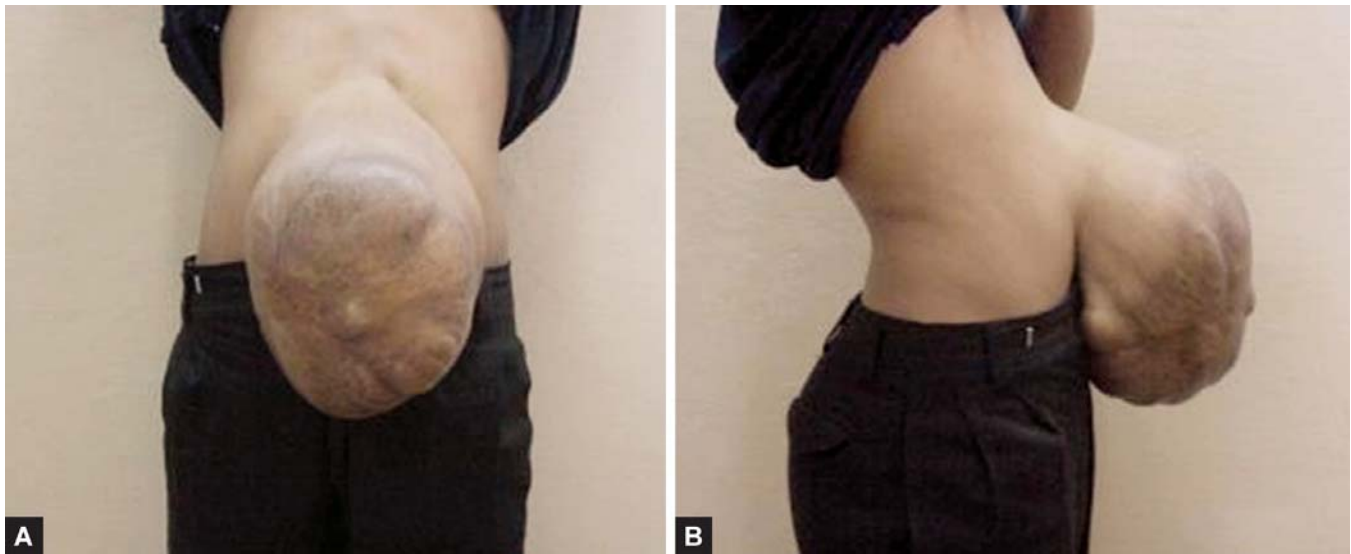Phantom Hernia

The size of the ventral hernias may be so huge that the abdominal cavity never got a chance to grow, and all the abdominal contents remained in the sac and grew outside the abdomen. It is thus impossible to reduce the hernial contents into the abdominal cavity due to lack of space (Figs 47.2A and B). Such cases should first be investigated for evaluating the position of great vessels, the kidneys and the liver by CT/MRI and nuclear scans. The management should be staged; first allowing the skin from lateral abdominal wall to enlarge in size with the use of tissue expanders, then the hernia is repaired with or without the mesh to bridge the gap between the rectus muscles.

In neglected cases, a severe lumbar lordosis may well become an alternative factor to produce visceroperitoneal disproportion observed before surgery, and its correction after surgery may well induce the abdominal cavity to rapidly enlarge.¹⁶ It may be speculated that the dehiscence of abdominal rectus muscles associated with omphalocele causes the tension of ventral muscles to decline and then, imbalance in tension between ventral (abdominal) and dorsal (back) muscles causes the lumbar lordosis to increase. Thus, during the staged procedure, the prosthetic sheet should be attached under moderate tension, and its plication should be carried out at regular intervals to maintain the tension of abdominal rectus muscles.¹⁶

INCISIONAL HERNIA

Iatrogenic hernia in general, occurs in 2-10% of all abdominal operations secondary to breakdown of the



Figs 47.2A and B: A ten-year-old boy presenting with postomphalocele large ventral hernia with a narrow neck and severe lumbar lordosis. The CT scan showed presence of most intestinal loops and the liver in the sac outside the abdomen. The vertebral spine, the aorta and the inferior vena cava were found displaced anteriorly to the level of the anterior abdominal wall

fascial closure of wound to the prior surgery. Even after repair, recurrence rates approach 20-45%. However, its incidence of incisional hernia in children is much lower due to good muscle strength, better wound healing ability and the routine practice of skin crease incisions.

While having an access to the kidneys, the intercostal nerve which lies posteriorly immediately below the last rib in between the internal oblique and the transverse abdominal muscles, an effort should be made to spare this nerve by dissecting both proximally and distally, enabling careful padding and traction of the nerve out of the operative field. The division of the nerve leads to muscle denervation and lumbar hernia. Postoperatively, the muscle denervation leading to the flank bulge must be differentiated from the flank incisional hernia, which is rare. In the later instance, a fascial defect is usually palpable. Most importantly, wound infection accounts for the majority of incisional hernias.

SPIGELIAN HERNIA

This rare form of abdominal wall hernia occurs through a defect in the spigelian fascia, which is defined by the lateral edge of the rectus muscle at the semilunar line (from costal arch to the pubic tubercle).

LUMBAR HERNIA

Lumbar hernias are also known as posterior body wall hernias (Figs 47.3 and 47.4). Congenital lumbar hernia is a rare anomaly with only 45 cases reported in the English-language literature.¹⁷ Hernias in the lumbar region are classified as; (1) Those through the superior lumbar triangle (of Grynfeltt-Lesshaft) and (2) Those through the inferior lumbar triangle (of Petit). Superior lumbar hernias are more commonly reported.¹⁸ However, some series have reported a relatively high incidence of inferior lumbar hernia.¹⁷

Hernia through the Superior Lumbar Triangle (of Grynfeltt-Lesshaft)

It is an inverted triangle, larger in size, more constant, most common site of lumbar hernia, contains T12 and L1 nerves and is avascular. A superior lumbar hernia is a protrusion of preperitoneal fat or peritoneum with sac formation or a viscus through the lumbar area just below the 12th rib.

The base of the triangle is the 12th rib and serratus posterior inferior muscle. The anterior boundary is the posterior border of the internal oblique muscle, posterior boundary is the anterior border of the sacrospinalis muscle. The floor of the triangle is formed

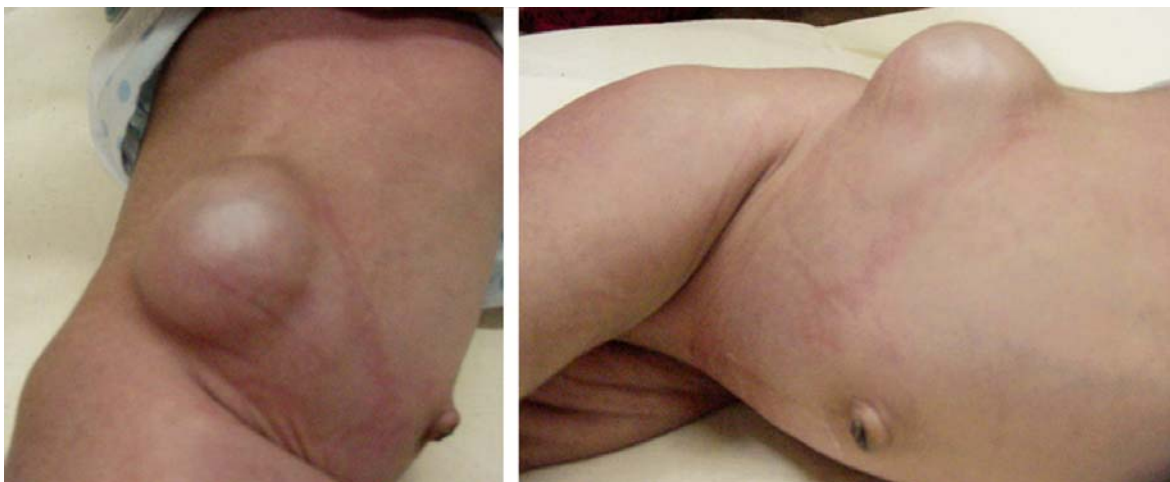

Fig. 47.3: Right side lumbar hernia in a 1-month-old child. There was a well defined circular defect in the abdominal wall muscles. With adequate mobilization, the defect could be closed primarily

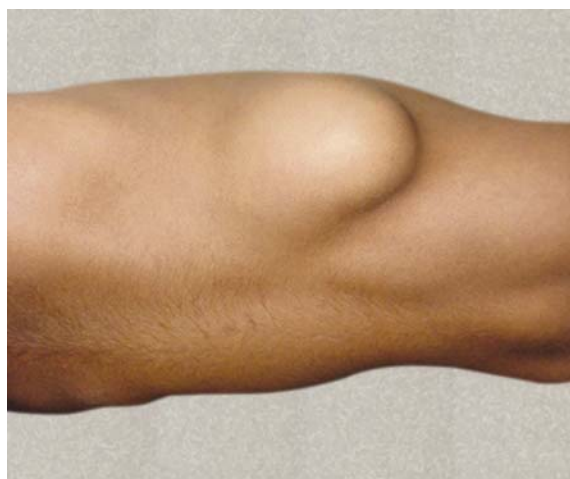

Fig. 47.4: The lumbar hernia in a child, with a circular defect in the abdominal wall muscles. The defect was repaired primarily with success

by the aponeurosis of the transversus abdominis muscle arising by fusion of the layers of the thoracolumbar fascia formed by the external oblique and latissimus dorsi muscles.

Hernia through the Inferior Lumbar Triangle (of Petit)

The base of the triangle is the iliac crest. The anterior (abdominal) boundary is the posterior border of the external oblique muscle. The posterior (lumbar) boundary is the anterior border of the latissimus dorsi muscle. The floor of the triangle is formed by the internal oblique muscle with contributions from the

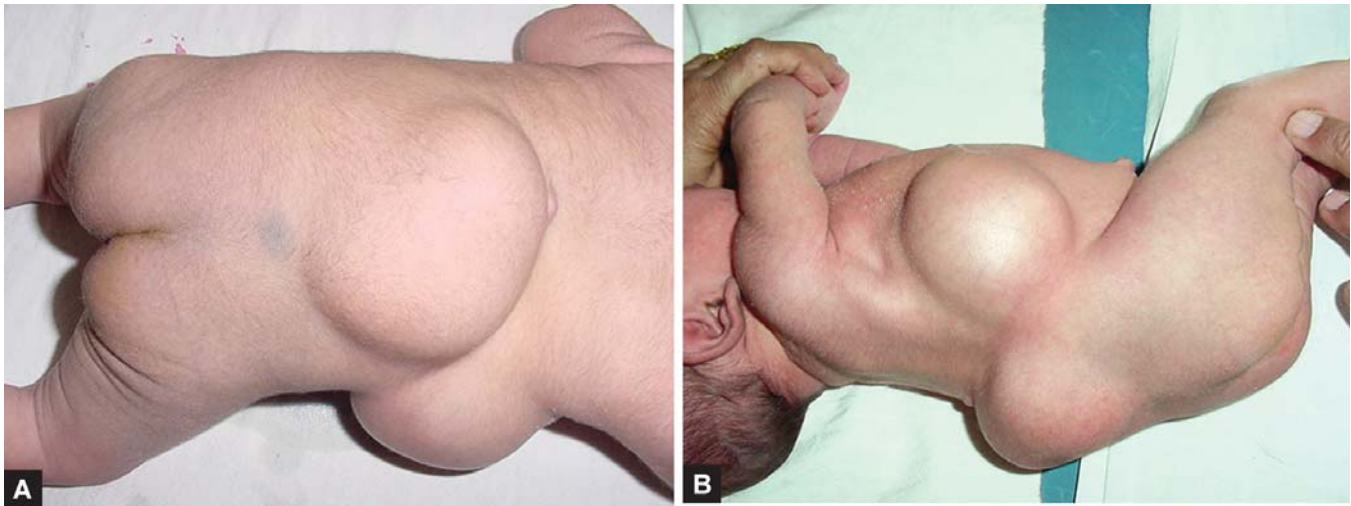
transversus abdominis muscle and posterior lamina of the thoracolumbar fascia and the internal oblique muscle. The triangle is covered by superficial fascia and skin. This is smaller in size, least common site of lumbar hernia, contains no nerves but is vascular. If the hernia through this triangle is small the ring is formed by the thoracolumbar fascia and fibers of internal oblique muscles. If it is large, the ring may include the boundaries of the whole inferior triangle. Enlargement of the ring is by section of the fascia.

Associated Anomalies

Congenital variants have been described, frequently associated with musculofascial and skeletal abnormalities, specifically "lumbocostovertebral syndrome" and/or meningocele (Figs 47.5A and B).¹⁹ The defect results from a single somatic defect occurring during the third to fifth week of embryonal development. As there are various reports on its association with the lumbocostovertebral syndrome, a spinal X-ray and/CT scan may be done to rule out the additional defects.²⁰⁻²²

Meningocele may predispose to lumbar herniation secondary to abnormalities in muscular innervation related to nerve entrapment in the spinal dysraphism.¹⁹

The lumbar hernias may also be associated with the defects in the thoracic cage. The associated anomalies of the ribs and the vertebrae may be extensive and large enough for the liver, lungs, kidney and spleen (left sided) to herniate outside. There may



Figs 47.5A and B: Right side lumbar hernia in a newborn baby associated with meningomyelocele

be paradoxical breathing resulting in respiratory distress, especially in the newborns (Figs 47.6A and B). The large defects involve absence, deficiency, twisting, widening, deformity and the fusion of the remaining ribs. On the right side, the defect may be covered with a large right lobe of the liver and may remain asymptomatic. However, as the important structures in the hernia sac remain unprotected and remain at risk to trauma, a surgical repair at an appropriate time is warranted. The closure of the defect involves approximation of ribs and the muscles as much as possible it could be done comfortably. The remain defect should be closed with a mesh. If the defect is small and less than 5 cm in diameter, there is no problem with the paradoxical breathing and no stabilization is required. However, large defects, more than 5 cm in size require stabilization of the chest. This could be accomplished by utilizing the available deformed, flat and/fused ribs to shape them appropriately by splitting, twisting or angulating them to support the mesh graft.

The hernia may be an isolated defect in the lumbar region, well circumscribed or it may be associated with hydrometrocolpos, meningomyelocele, anorectal malformation, undescended testis and multiple other anomalies.^{17,18,20} The diagnosis of the hernia may be delayed due to its juxtaposition to a posterior meningomyelocele and may result in incarceration.²⁰ Acquired lumbar hernia generally can be attributed to surgery,

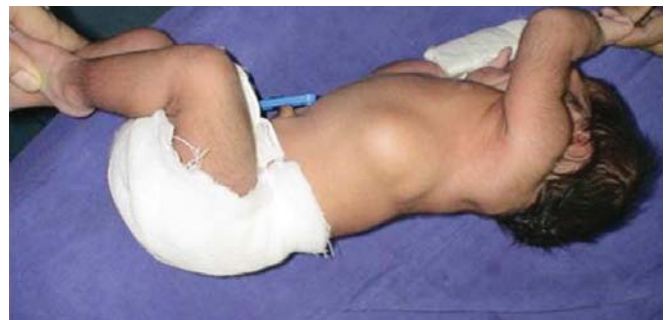

Fig. 47.6A: Thoracolumbar hernia in a newborn presenting with respiratory distress

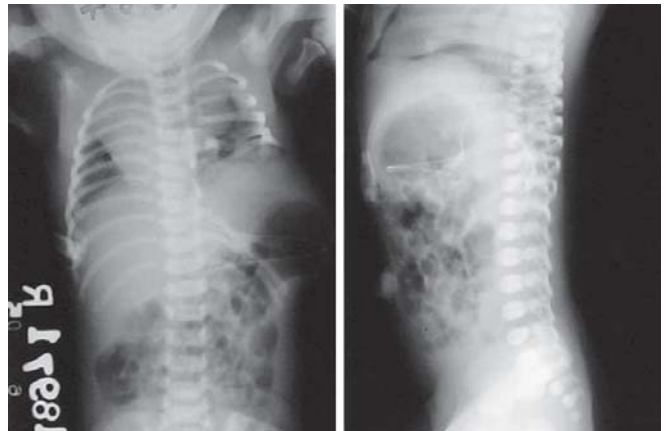


Fig. 47.6B: Skiagram showing defect in the rib cage on the left side of the chest. There was herniation of left lung, left lobe of the liver, left kidney and the spleen through the defect. The diaphragm was thin and amuscular. The hernial defect was repaired and the gap was covered using ribs from the lower thoracic cage

infection, or trauma. Localized neuropraxis, temporary or permanent, may be the underlying factor, common to all these defects. Lumbar hernia associated with intrathoracic neuroblastoma have also been reported. The lumbar hernia is also reported to have resulted from neuropraxis secondary to intrathoracic paravertebral tumor and its management. In both cases, this deficiency was temporary and resolved without specific therapy. These cases suggest a role for conservative treatment for the hernia itself, when the neural impairment resulting in the defect is of a temporary nature.¹⁹

Investigations for a lumbar hernia include ultrasonography, barium enema and small bowel contrast studies to rule out hydronephrosis or renal lump; bowel content, etc. A dorsal and lumbosacral X-rays may be done to rule out vertebral pathology.

REPAIR

Early operation is the treatment of choice, and repair with local tissues is preferable.¹⁷ The need for prosthetic material arises when the size of the defect is more than 5 cm in diameter and the defect can't be closed primarily.¹⁷ A successful operation by mobilization and approximation of the muscle edges offers a good quality of life.¹⁷ Operative repair is recommended for these patients before 12 months of age.¹⁸

The repair is done with the patient in the lateral kidney position with the hernia side up. The affected flank is extended by extension of the ipsilateral lower extremity and flexion of the opposite extremity at the knee. The choice of the repair material depends upon the size of the defect. For small defects, the defect in the thoracolumbar fascia and muscles is repaired with nylon. For large hernias, a flap graft or a mesh (single or double) or both may be used. The authors have rotated the distal ends of the 10th and 11th ribs to support the thin muscular repair in a case of large defects.

Dowd-Ponka Repair of Lumbar Hernia²³

An oblique or vertical incision is given over the hernia site. In superior hernia, the sac lies beneath skin, superficial fascia, and latissimus dorsi muscle. In inferior hernia, there is no layer of muscle. The hernial

sac, if present, is ligated with silk (3-0) and replaced in the abdomen. If a large lipoma is present, a purse-string suture or several interrupted sutures will keep the fat down. A Marlex or Prolene patch is placed over the defect and sutured to the external oblique and latissimus dorsi muscles and lumbar periosteum using interrupted nylon/prolene.

The external oblique and latissimus dorsi muscles are approximated over the Marlex patch as far as possible without tension. A flap of gluteal fascia is turned up to cover the remaining defect and secure it with interrupted nylon sutures to the muscles present. A large hernial ring may require a second layer of Marlex mesh sutured to the muscles.

INTERNAL HERNIAS IN THE ABDOMEN

Internal abdominal hernias are uncommon varieties of hernias. These are difficult to detect and also remain mostly asymptomatic. They have confusing anatomy and obscure etiology. They account for about one percent of all cases of intestinal obstruction.

Two types of internal hernias may be encountered:

1. The passage of a viscus through a defect either in a mesentery or the omentum.
2. Protrusion of a viscus through an opening formed by a fold of peritoneum.

Hernias through Mesenteric or Omental Defect

These have been called 'false hernias' as there is no hernial sac. All mesenteries in the abdominal cavity are subject to defects through which herniation may take place. These defects may be developmental or as the result of trauma. The chief locations are through the mesentery, greater omentum, sigmoid mesocolon, broad ligament of the uterus or the falciform ligament. Paraduodenal herniation is the most common.²⁴ These hernias are asymptomatic unless incarcerated. The frequency of internal herniation is given in Table 47.1.

Table 47.1: The frequency of internal herniation

Paraduodenal	42-53%
Paracecal	13%
Through the epiploic foramen	8%
Transmesenteric	8%
In the sigmoid region	6%
Other congenital and acquired hernias	12%

The hernia may start in the relatively avascular areas of the mesentery. The defect then enlarges until at least one free edge is formed by an important artery. It is usually a branch of the superior or the inferior mesenteric artery. In many cases, an intestinal loop may pass freely through the defect without any strangulation. However, adhesions may develop between the hernial ring and the herniated intestinal loop, making it vulnerable to symptoms due to strangulation.

Omental herniation can occur between arc of Barkow and any of the descending arteries. For the repair, the ring is enlarged between clamps. The omentum is incised and the bowel is freed. The hernia is reduced and the clamped tissue is suture ligated. The defect in the omentum must be closed with continuous or interrupted sutures to prevent recurrences. Decompression of the proximal intestine without incising the ring may also permit reduction of the herniated loop and closure of the omental defect.

Rarely the loops of the small bowel, appendix, cecum, and the ascending colon may be placed within the anterior and posterior leaves of the un-fused greater omentum. Appendectomy and the resection of the sac should be performed to achieve successful outcome. Embryologically, anatomically and clinically, the intra-mesenteric hernias may take place in any part of mesentery that has congenital openings or pouches. Hernia at the terminal ileum (pouch of Treves') is one such example. It may enlarge to house the intestinal loops in the pouch.

Mesenteric herniation takes place through defect in mesentery of small intestine, transverse mesocolon and most commonly the sigmoid mesocolon. At least one free edge of the ring is usually formed by a branch of the superior mesenteric or the inferior mesenteric artery. Since there is no sac, the obstructed loops are clearly visible. Any injury to the vessel at the edge of the defect must be avoided. The dilated loop needs to be decompressed first before reducing the hernia. The vascular injury must be avoided.

Hernias beneath a Mesenteric or Peritoneal Fold

In this second group of internal hernias there is no break in the peritoneum, the herniated viscus enters and enlarge a naturally occurring fold or pocket of peritoneum. A sac is always present.

A. *Hernia through the epiploic foramen of Winslow:* For unknown reasons, this hernia is extremely uncommon in children despite of the fact that the epiploic foramen is normally open. The boundaries of the foramen are; superiorly the caudate process, anteriorly the hepatoduodenal ligament containing portal triad, posteriorly the inferior vena cava and inferiorly the first part of the duodenum and the transverse part of the hepatic artery. The neck of the ring should not be incised under any circumstances. To reduce the hernia, the hepatogastric ligament is opened and the incarcerated intestine is decompressed carefully taking all care not to allow contamination. After the decompression of the bowel has been achieved, the aspiration site is closed with a purse string suture. The hernia is reduced and the defect in the hepatogastric ligament is closed. Fixation of an abnormally mobile cecum or right colon may be helpful to avoid recurrences.

B. *Hernia through the transverse mesocolon:* The herniated loop enters lesser sac to the left of the middle colic vessels called space of Riolan.

C. *Paraduodenal hernias:* Abdominal cavity is full of pouches and fossae. Moynihan in 1889 described nine fossae or peritoneal pockets which form potential spaces for internal herniations.²⁵ Only five of these fossae are constant enough to be of clinical importance and have been outlined below in Table 47.2. These hernias, though rare, have been reported in children.²⁶

Paraduodenal hernias are formed during the period of fixation of colon (by 5th month of the fetal life). They are known by the direction of the herniated loop, if the loop passes to the right, it is a right paraduodenal hernia; without reference to the midline of the body or to the specific fossae concerned. Paraduodenal sacs usually contain

Table 47.2: The five paraduodenal fossae

Fossa	Direction of Hernia	Incidence (%)
1. Superior duodenal fossa of Treitz	Right	30-50
2. Paraduodenal fossa of Landzert	Left	2
3. Inferior duodenal fossa of Treitz	Right	50-70
4. Intermesocolic fossa of Broesike	Right	Rare
5. Mesentericoparietal fossa of Waldeyer	Right	01

small intestine, though rarely may contain cecum, ascending colon or sigmoid colon. The surgical treatment of strangulated paraduodenal hernia includes the reduction of the hernia and the eradication of the fossa. This may be performed either by closing the neck of the fossa or by enlarging the orifice so that there are no chances of the pouch formation. Injury to major blood vessels must be avoided. Enterostomy may be required for decompression of the contents of the hernia. The herniated contents should be looked carefully for the viability and an appropriate action should be taken if the need be.

D. *The paracecal hernias:* Six fossae are related to the cecum.

1. Superior ileocecal fossa
2. Inferior ileocecal fossa
3. Retrocecal or retrocolic fossa
4. Hartmann's fossa
5. Paracolic fossa
6. Iliaco-subfascialis.

Out of these, first two are important. Superior ileocecal fossa is formed by superior ileocecal fold of ileocolic mesentery and contains the anterior branch of the ileocolic artery. The inferior ileocecal fossa has an anterior prominent ileoappendicular fold which occasionally contains the ileoappendicular artery. The hernial sac may be found under the cecum.

COMPLICATIONS

Rare hernias through narrow necks like femoral hernia and internal hernias are prone to complications if not identified and treated in time once the symptoms appear. The reason being rarity of the lesion, the abnormal sites and the difficulty in making the diagnosis without surgery. Hernias visible outside the abdominal cavity may be examined for risk of complications. Reducible hernia refers to the ability to return the contents of the hernia into the abdominal cavity, either spontaneously or manually. An incarcerated hernia is no longer reducible. The vascular supply of the bowel is still not compromised, though the symptoms due to bowel obstruction are common. A strangulated hernia when the vascular supply of the bowel is compromised secondary to incarceration of hernia contents, poses a serious challenge.

Complications following repair of the hernia are many and most are avoidable. These include;

1. Vascular complications like seroma or hematoma formation though uncommon in children, still can happen rarely. Main vessel may also be injured if it is included in the clamp while widening the neck of the sac.
2. Neurological injury of the nerves may occur in the close proximity, e.g. T12 or L1 nerves during repair of a lumbar hernia through the superior lumbar triangle.
3. Injury of the hollow viscus (most likely the colon) is likely to happen if the hernia is incarcerated or is of a sliding type. This is likely to happen during the opening of the sac, or by taking deep bites of the protruding fats.
4. Recurrence of the hernia is likely to occur if the anatomical details have not been kept in mind while making a diagnosis or repairing the defect.
5. Infection of the wound or even peritonitis, is a serious threat if the bowel gets injured during surgery.

REFERENCES

1. Schier F, Klizaitis J. Rare inguinal hernia forms in children. *Pediatr Surg Int* 2004;20:748-52.
2. Shonubi AM, Musa AA, Salami BA, et al. Femoral hernias in children at the Olabisi Onabanjo University Teaching Hospital, Sagamu, Nigeria. *East Afr Med J* 2004;81:447-49.
3. Radcliffe G, Stringer MD. Reappraisal of femoral hernia in children. *Br J Surg* 1997;84:58-60.
4. Al-Shanafey S, Giacomantonio M. Femoral hernia in children. *J Pediatr Surg* 1999;34:1104-06.
5. Ollero Fresno JC, Alvarez M, Sanchez M, et al. Femoral hernia in childhood: review of 38 cases. *Pediatr Surg Int* 1997;12:520-21.
6. De Caluwac D, Chertin B, Puri P. Childhood femoral hernia: a commonly misdiagnosed condition. *Pediatr Surg Int* 2003;19:608-9.
7. Asai A, Takehara H, Okada A, et al. A case of femoral hernia in a child. *Tokushima J Exp Med* 1992;39:145-47.
8. Fonzone Caccese A, Caccioppoli U, Aliotta A, et al. Femoral hernia in childhood: a rare entity. *Pediatr Med Chir* 1999;21:145-48.
9. Dattola P, Alberti A, Dattola A, et al. Inguino-crural hernias: preoperative diagnosis and postoperative follow-up by high-resolution ultrasonography. A personal experience. *Ann Ital Chir* 2002;73:65-68.
10. McVay CB, Savage LE. Etiology of femoral hernia. *Ann Surg* 1961;154:25-32.
11. Lichtenstein IL, Shore JM. Simplified repair of femoral and recurrent inguinal hernias by a 'plug' technique. *Am J Surg* 1974;128:439-44.

12. Ceran C, Kaylaoaylu G, Sanmez K. Femoral hernia repair with mesh-plug in children. *J Pediatr Surg* 2002;37:1456-58.
13. Schier F. Laparoscopic inguinal hernia repair-a prospective personal series of 542 children. *J Pediatr Surg* 2006 June;41(6):1081-84.
14. Lee SL, DuBois JJ. Laparoscopic diagnosis and repair of pediatric femoral hernia. Initial experience of four cases. *Surg Endosc*. 2000 Dec;14(12):1110-13. Comment in: *Surg Endosc* 2000 Dec;14(12):1097.
15. Mishalany HG, Pereyra R, Longerbean JK. Littre's hernia in infancy presenting as undescended testicle. *J Pediatr Surg* 1982;17:67-69.
16. Nagaya M, Kato J, Niimi N, Tanaka S. Lordosis of lumbar vertebrae in omphalocele: an important factor in regulating abdominal cavity capacity. *J Pediatr Surg* 2000;35:1782-85.
17. Wakhlu A, Wakhlu AK. Congenital lumbar hernia. *Pediatr Surg Int* 2000;16:146-48.
18. Pul M, Pul N, Garses N. Congenital lumbar (Grynfelt-Lesshaft) hernia. *Eur J Pediatr Surg* 1991;1:115-17.
19. Lafer DJ. Neuroblastoma and lumbar hernia: a causal relationship? *J Pediatr Surg* 1994;29(7):926-29.
20. Hancock BJ, Wiseman NE. Incarcerated congenital lumbar hernia associated with the lumbocostovertebral syndrome. *J Pediatr Surg* 1988;23(8):782-83.
21. Somuncu S, Bernay F, Rizalar R, Aritürk E, Günaydin M, Gürses N. Congenital lumbar hernia associated with the lumbocostovertebral syndrome: two cases. *Eur J Pediatr Surg* 1997;7(2):122-24.
22. Akçora B, Temiz A, Babayigit C. A different type of congenital lumbar hernia associated with the lumbocostovertebral syndrome. *J Pediatr Surg* 2008; 43(1):e21-23.
23. Ponka JL. *Hernias of the abdominal wall*. WB Saunders. Philadelphia 1980;532-53.
24. Skandalakis LJ, Gadaez R Thomas, Mansberger RA, Mitchell EW. *Modern Hernia Repair. The embryological and anatomical basis of surgery* 1996;388.
25. Moynihan BGA. *Retro-peritoneal Hernia*, Balliere, London 1889.
26. Gomez-Fraile A, Cuadros J, Matute JA, et al. Paraduodenal hernia in childhood. *Pediatric surgery International* 1989; 4:286-87.